

The Use of Power Equipment in Equine Dentistry

Gordon J. Baker, BVSc, PhD, MRCVS, Diplomate ACVS; and
Martin L. Allen, DVM, MS

The proper use of powered equine dental devices has been shown to be of great value to the equine practitioner. It is important that the veterinary clinician keeps all aspects of the safe use of such equipment in mind when it is employed in equine dentistry. Author's address: University of Illinois College of Veterinary Medicine, 218 LAC, 1008 W. Hazelwood Drive, Urbana, IL 61802. © 2002 AAEP.

1. Introduction

The subject of equine dentistry has attracted considerable attention in the past two decades. We have witnessed a healthy interest in the subject from veterinarians, technicians, owners and trainers, and a desire to learn and understand more about dentition, dental diseases, and their treatment. AAEP has been at the forefront of presenting science and discussion into what has been, for some time, subjects of controversy. There has been considerable development of equine dental equipment reflecting this interest in equine dentistry and the role it has as a vital part of health maintenance programs for horses. Electrical (outlet power or rechargeable battery packs) and air-driven power equipment have made the practice of dentistry, in particular the floating of teeth, a less physically demanding task. Their use, supplemented by head restraints, better specula, better lighting systems, and intravenous sedatives/analgesics have all improved the quality of equine oral examinations and dental treatments.^{1,2} This report will discuss the advantages, potential disadvantages, and guidelines for the efficient use of power equipment in equine dentistry.

2. Safety

As in all manipulative procedures in horses, it is important to establish an understanding with your patient before attempting any potentially disturbing, distressing, or painful procedure! For most practitioners such doctor/patient interactions are the fundamentals for good-quality equine practice. One advantage of employing power tool techniques is that procedures may be carried out in a shorter period of time and well within the sedative/analgesic timeframe of alpha agonist drugs. Experience has shown that many combinations and variations have found their supporters in equine dentistry. In a trial comparing xylazine to detomidine, in a blinded, controlled study, both drugs were equally suitable in producing sedation and control to facilitate dental prophylaxis (xylazine 0.5 mg/kg and detomidine HCl 10 mg/kg).³ Many practitioners supplement 10–20 mg/kg butorphanol to enhance the level of analgesia.⁴

A good starting guide is the “two foot rule,” i.e., after sedation the horse should be relaxed and its lips should be lowered to two feet from the floor). The head is then supported in an appropriate head stand and a full-mouth speculum inserted. At no time should the owner or caretaker be allowed

NOTES

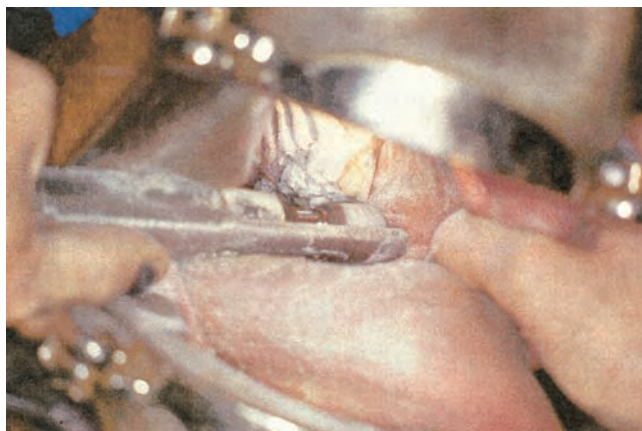


Fig. 1. Rotary burr.

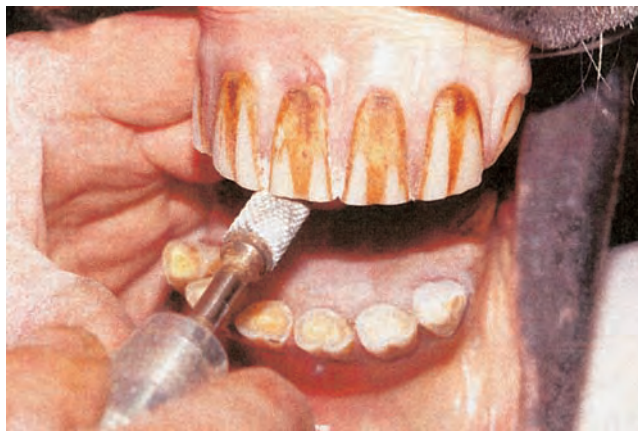

Fig. 2. Incisor reduction (From, with permission: Scrutchfield WL. Equine dental instrumentation. In: Baker and Easley, eds. *Equine dentistry*. Philadelphia: W. B. Saunders, Philadelphia. 1999;173–184).

to assist. The best work is done by the practitioner with trained technicians as the treatment aid.

In all circumstances, properly grounded electrical sources must be employed for all non-battery powered or air-driven power equipment. Safety goggles should be used and a nasal mask should be worn to avoid the inhalation of tooth powder. There is evidence that suggests a carcinogenic effect of inhaled tooth powder. It cannot be emphasized enough that, for the new user of power equipment, there is a steep learning curve. Practice on cadaver specimens, dental refresher courses and first-hand learning from experienced colleagues are all recommended and, the author believes, are essential in mastering the subtleties of power equipment technology.⁵

A number of rotating grinders have guarded attachments to protect the oral soft-tissues from iatrogenic trauma. It is essential that the grinding process, angle, and position of the blade(s) are clearly visible to the operator before grinding is commenced (Fig. 1).

In general, there are two types of power equipment—reciprocating and rotary. Rotary types drive both burrs and discs (Fig. 2). The stroke length of the reciprocating blades varies from 0.4 to 3.2 cm, depending upon the manufacturer. Blade and burr speeds range from 2000 to 9000 strokes, or cycles, per minute. Practitioners are advised to try a range of equipment and then, with advice, to select a range that suits their own practice requirements.

It has been shown that, in human dentistry and animal models, that crown reduction using power equipment creates heat. It has been reported that a 5.5°C increase in pulp temperature created protein denaturation and irreversible damage in 15% of the human teeth tested.⁶ In another study on the conduction of the thermal effect of CO₂ laser on teeth, dentinal tubules and pulp tissue, it was found that a rise in pulp temperature of 16.3°C resulted in pulp necrosis in 100% of teeth examined.⁷

Because horse teeth are continuously erupting, and crown structure is worn away by the grinding action of the teeth, all hypsodont teeth need living pulp to protect the tooth from pulp exposure. Pressure, chemical and thermal stimuli are conducted via the dentinal tubules to the odontoblasts lining the pulp chambers. In response to these stimuli, secondary dentine is laid down by the odontoblasts and the size of the pulp chambers is reduced (Fig. 3). Such actions may be seen on the occlusal surfaces of the teeth (i.e., appearance of dental stars on incisors). It is therefore important to avoid thermal injury to the pulp tissues whenever tooth crowns are reduced. In a recent study, working *in vitro* on mandibular cheek teeth into which 38 gauge copper—constantan thermocouples were placed adjacent to the dentinal/pulp junction and the thermal effect of tooth reduction with power equipment was monitored. The thermocouples were placed 15 mm and 25 mm from the occlusal surface. Groups of teeth were subjected to 1-min and 2-min power reductions by using a disc burr power floating system,

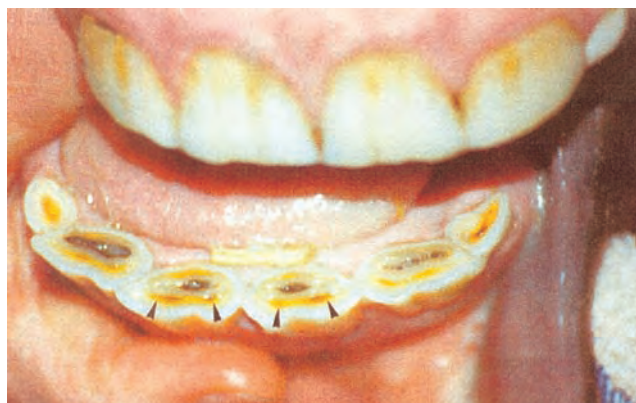


Fig. 3. Secondary dentin seen as the dental stars (arrows).

DENTISTRY

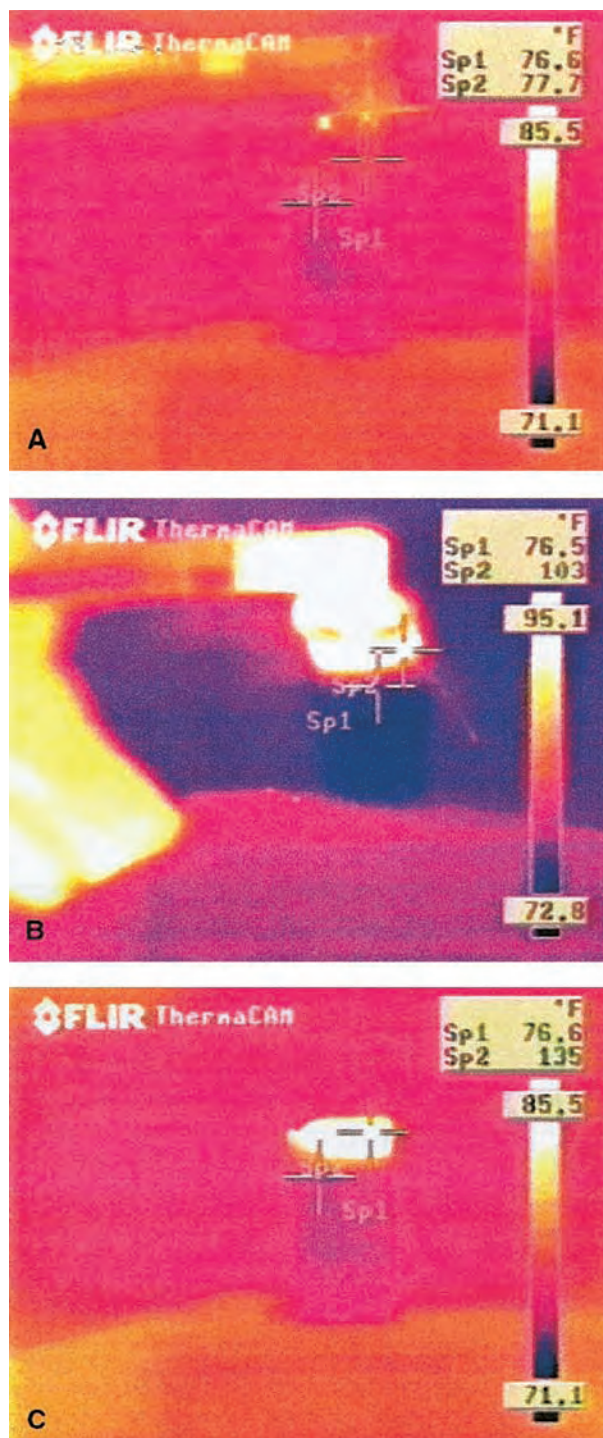


Fig. 4. Thermal images of temperature changes from power reduction. (a) Rest. (b) One-minute reduction. (c) Two-minute reduction.

fitted with a 26-mm carbide blade used at a rotational speed of 4000 rpm. The thermal changes were noted and the experiments repeated by using a water-cooling system (20.3°C water delivered at 20 ml/min). The results showed that the 1-min reduction yielded 6.6°C (average) increase from the coro-

nal thermocouple and 1.2°C (average) increase from the more apical thermocouple. The 2-min reduction produced average temperature increase of 24.3°C and 4.06°C, respectively (Fig. 4). The application of water cooling eliminated all potentially pathogenic, thermal effects.⁸

It may be seen from these experiments that routine dental prophylaxis by using power equipment does not create pathogenic thermal effects.⁸ However, the 2-min reduction, the equivalent of major hook, ramp, crown reductions, bit seat construction, or incisor reduction can create thermal pulp trauma. Care must be taken, therefore, to minimize contact time and supplement major dental reductions with irrigations. Careful burr cleaning and maintenance will also help to reduce the occurrence of thermal injuries. It may not be necessary to have continuous irrigation, although, grounding of the electrical equipment will protect from electrical hazards, but in all major power work, intermittent contact time and cooling irrigation is recommended.

In discussing potential thermal injuries it has often been said that they do not occur. However, in a referral dental clinic, a number of cases of dental decay have been recorded subsequent to crown-reduction procedures. These are rarely seen or referred early after the dental procedure. The rate of crown attrition and eruption ensure that the tooth is sound until at least 6.0–8.0 mm of the tooth has erupted post the reduction. This may take as long as 3 yr. Hence, the connection between pulp decay from thermal injury and presentation as a clinical case of dental decay may not be made. Careful inspection, for example, of vigorous bit seat construction may demonstrate a “blush” across the exposed dentine, indicating how close the procedure came to exposing the mesial pulp horns.

Emphasis has already been placed on the value and need for competent and trained assistance when using power equipment. The choice of equipment needs also to be selected to match the physical size, conformation, and strength of the operator. By taking care of your leg and lumbar spine position, shoulder, elbow, and wrist positions, the equine dentist will avoid the potential for such repetitive stress injuries as carpal tunnel syndrome, digital flexor tendinopathies, lateral humeral epicondylitis (“tooth floaters elbow”), and rotator cuff impingement trauma. Avoid working with your arms in full extension with tight flexion, keep the elbows tucked in and below the level of the shoulders.

References

1. Scrutchfield WL. Dental prophylaxis. Baker GJ, Easley J, eds. *Equine dentistry*. Philadelphia: W.B. Saunders 1999;185–205.
2. Pence P. Dental equipment. In: *Equine dentistry. A practical guide*. Chapter 2. Philadelphia: Lippincott, Williams and Wilkins, 2001.
3. Baker GJ, Kirkland KD. Sedation for dental prophylaxis in horses: a comparison between detomidine and xylazine, in

DENTISTRY

- Proceedings*. 41st Ann Convent Am Assoc Equine Practition 1995;40-41.
4. Lowder MA. How to perform oral extraction of equine cheek teeth, in *Proceedings*. 45th Annu Convent Am Assoc Equine Practition 1999;131-136.
 5. Scrutchfield WL. Equine dental instrumentation. In: Baker GJ, Easley J, eds. *Equine dentistry*. Philadelphia: W. B. Saunders. 1999;173-184.
 6. Zach L, Cohen G. Pulp response to externally applied heat. *Oral Surg* 1965;19:515-530.
 7. Jeffrey WM, Lawrenson B, Saunders EM, Longbottom C. Dentinal temperature transients caused by exposure to CO₂ laser irradiation and possible pulp damage. *J Dent* 1990;18:31-36.
 8. Allen ML. An *in-vitro* study of heat production in equine teeth from power reduction. M.S. Thesis, University of Illinois, 2001.