

► **From the Horse's Mouth** features important topics on equine dentistry



Routine Dentistry in Juvenile Performance Horses

►► **Cleet Griffin, DVM, DABVP**
Texas A&M University

Abstract: In horses, eruption of the permanent dentition begins at approximately 1 year of age and is completed by approximately 5 years of age. Because juvenile horses in work can develop undesirable behaviors due to oral pain, veterinarians frequently perform oral examinations to identify dental conditions that may be problematic. In juvenile horses, dental concerns include the presence of wolf teeth, sharp dental points, mucosal erosions, abnormalities of eruption, and facial swellings. Veterinarians perform procedures designed to alleviate sources of oral pain, such as smoothing (floating) of sharp areas, extraction of wolf teeth, and removal of retained deciduous teeth. Sometimes, radiography is indicated to provide more information about areas of concern identified by the examiner. To most effectively perform oral examinations and common dental procedures in young horses, veterinarians should have a working knowledge of skull anatomy, dental anatomy, and tooth eruption times.

At a Glance

► **Anatomy and Nomenclature**

Page 402

► **Examination**

Page 406

► **Routine Dental Conditions in Juvenile Performance Horses**

Page 408

In horses aged 1 to 5 years, the permanent cheek teeth (24) and incisors (12) erupt sequentially, causing the deciduous cheek teeth and incisors to shed during this time. At approximately 2 years of age, many horses begin training for competitive, strenuous athletic events. Veterinarians and horse owners associate several undesirable behaviors (e.g., head tossing) with oral pain in these horses. Therefore, veterinarians are often asked to examine juvenile (2 to 5 years of age) horses' mouths to identify sources of pain, to evaluate facial or mandibular swellings, and to identify abnormalities associated with adult tooth eruption. To treat these horses, veterinarians remove (float) sharp dental points and extract wolf teeth, remove retained deciduous incisors, and remove loose, retained, or damaged deciduous premolars. In most cases, the veterinarian's goal for these dental procedures is to help juvenile horses perform (and chew) more comfortably. This article reviews the pertinent dental anatomy, nomenclature, and tooth eruption times in horses and describes the treatment of several common dental conditions in juvenile horses.

Anatomy and Nomenclature

See **BOX 1**¹⁻³ for equine dental formulas.

Incisors (Triadan '01 through '03)

The deciduous central incisors (Triadan '01) erupt at approximately 6 days of age, the deciduous intermediate incisors (Triadan '02) at 4 to 6 weeks of age, and the deciduous corner incisors (Triadan '03) at 6 to 9 months of age.⁴ The deciduous incisors are dome-shaped and are smaller and whiter than the permanent incisors (**FIGURE 1**). The deciduous incisors have a flattened root, short crown, and shallow infundibulum (cup) on the occlusal surface.^{1,2} As the permanent incisor erupts, the deciduous tooth root is resorbed. The deciduous incisor (cap) sheds as the permanent incisor emerges on the lingual side of the deciduous tooth. The eruption times of the deciduous and permanent incisors can be used to help estimate a horse's age.⁴

Canine Teeth (Triadan '04)

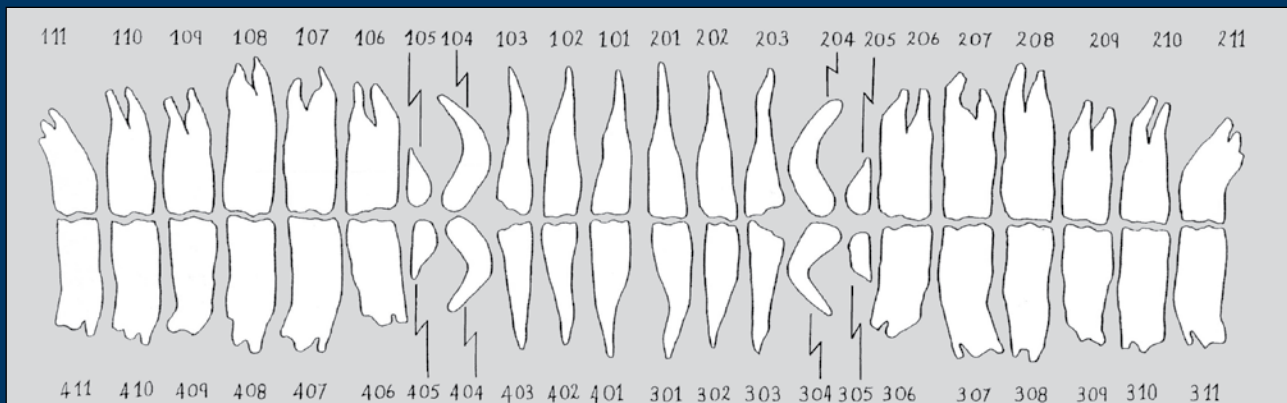
In both sexes, the deciduous canine teeth are short spicules (~0.5 cm in length) that do not erupt through the gingiva.¹ Permanent canine teeth erupt at approxi-

BOX 1

Triadan Tooth Numbering System

Using the three-digit nomenclature system, the first digit designates the quadrant of the mouth and whether a tooth is deciduous or permanent. The numbering sequence for permanent teeth is right maxilla, 1; left maxilla, 2; left mandible, 3; and right mandible, 4. The deciduous teeth are designated as quadrants 5 through 8 in the same order. The subsequent digits in the num-

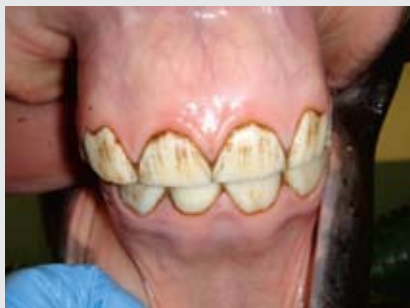bering system designate each tooth within the quadrant, starting with the central (first) incisor, which is designated as '01. The incisors are designated as '01 to '03; the canine teeth, '04; the premolars, '05 to '08; and the molars, '09 to '11 (e.g., the central incisor of the upper right arcade is 101, the intermediate incisor of the same arcade is 102).¹⁻³



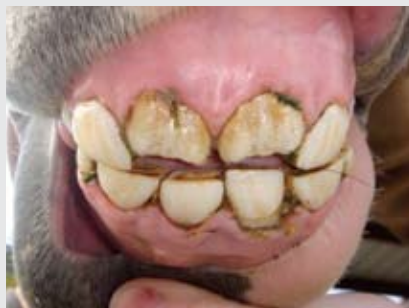Triadan classification of equine teeth. (From Floyd MR. The modified Triadan system nomenclature for veterinary dentistry. *J Vet Dent* 1991. Reprinted with permission from Baker GJ, Easley J, eds. *Equine Dentistry*. 2nd ed. Philadelphia: Elsevier; 2005)

FIGURE 1

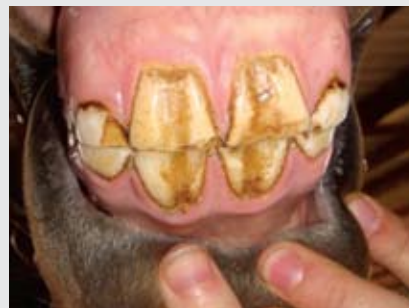The incisors.



Deciduous incisors in a 2-year-old Quarter horse. Deciduous incisors are dome-shaped and are smaller and whiter than permanent incisors.



The lower-left central deciduous incisor (Triadan 701) is being pushed away from the gingiva as the underlying permanent tooth emerges in an approximately 30-month-old horse. The upper-central deciduous incisors were already shed; the upper-central permanent incisors (Triadan 101 and 201) continue to erupt toward wear (occlusion).



The four permanent central incisors have come into wear in a 3-year-old horse. These teeth have vertical grooves and are significantly larger than the adjacent deciduous incisors.

mately 4 to 5 years of age and are consistently present in male horses.⁴ The adult canine teeth have a simple structure, including a long, curved crown (~6 cm in length), of which

only a short length erupts through the gingiva. Unlike the cheek teeth, the canine teeth do not continually erupt,⁵ and there is no occlusal contact between the upper and lower canine

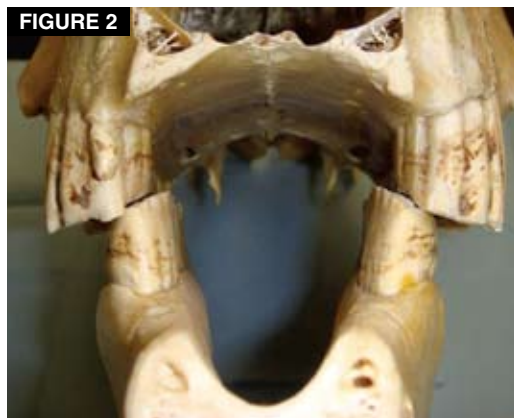

FIGURE 2
The relationship between the upper and lower cheek teeth in horses. The width of the upper and lower jaws differs, and the chewing surface is sloped (the maxillary cheek teeth are taller on the buccal side, and the mandibular cheek teeth are taller on the lingual side).

teeth because the lower canine teeth are more rostral than the upper teeth.

Wolf Teeth (Triadan '05)

The small, simply crowned wolf teeth (first premolars) do not have deciduous counterparts and generally erupt during the first year of life. These teeth are usually no more than 1 to 2 cm in length, are present in most yearling horses, and have a single root that may be up to 30 mm in length.⁵⁻⁷ The wolf teeth are usually near the rostral part of the second premolar (Triadan '06). In some cases, wolf teeth are shed during eruption of permanent second premolars.^{2,8} Wolf teeth may not be present in all of the dental arcades, making it possible for a horse to have zero to four wolf teeth. In some cases, wolf teeth do not erupt through the gingiva but remain as firm, submucosal nodules within the interdental space; these are called *blind* or *impacted wolf teeth*.

Cheek Teeth (Triadan '06 through '11)

In foals, the deciduous premolars (Triadan '06 through '08) erupt through the gingiva shortly after birth.⁴ The deciduous premolars undergo distinct root formation and have a much shorter crown than the permanent premolars.^{1,2} It is of clinical interest that the crowns of the deciduous premolars closely resemble those of the permanent teeth. As a juvenile horse matures, the crowns of the deciduous premolars wear thin, and the roots resorb as

the underlying permanent teeth erupt. A thin portion of the deciduous crown with slender, sharp root spicules (known as a *cap*) remains closely associated with the underlying permanent tooth as it works through the gingiva.⁵ As the permanent tooth erupts, a small gap develops between the permanent premolar and the cap, and the soft tissue attachments associated with the cap necrotize as wet feed material and bacteria become trapped in this space. Over time, the cap loosens and is shed. The permanent premolars erupt, and their deciduous counterparts subsequently shed sequentially at approximately 2½ years (Triadan '06), 3 years (Triadan '07), and 4 years (Triadan '08) of age.⁴ The molars (Triadan '09 through '11), which have no deciduous precursors, erupt at approximately 1 year (Triadan '09), 2 years (Triadan '10), and 3½ years (Triadan '11) of age.^{2,4} The permanent cheek teeth have long reserve crowns that continually erupt at 2 to 3 mm per year, which is similar to the rate of attrition at the chewing surface.⁵

In horses, the width between the two rows of maxillary cheek teeth is greater than the width between the two rows of mandibular cheek teeth; this discrepancy is called *anisognathia*.⁵ The angle of occlusion between the upper and lower cheek teeth is sloped in the lateromedial plane, with the upper cheek teeth being longer on their buccal aspect and the lower cheek teeth taller on their lingual aspect⁵ (FIGURE 2). This normal slope across the grinding surface of the cheek teeth is considered to be approximately 10° to 15°,⁵ although recent investigators have determined that the size and range of the slope (angle of occlusion) in normal horses is greater than previously thought.⁹ The combination of the anatomic differences between the upper and lower jaws and the chewing action of the horse forms sharp dental points on the buccal side of the upper cheek teeth and on the lingual side of the lower cheek teeth.

Examination

First assess the horse's health status by obtaining the pertinent history, performing a physical examination, and determining the horse's body condition score. Before sedating the horse for an oral examination, attempt to rinse its mouth, estimate its age, and identify incisor abnormalities (e.g., overgrown incisors that

CriticalPoint

Juvenile horses in work can develop undesirable behaviors due to oral pain.



FIGURE 3
Safe technique for palpating sharp dental points along the cheek.

may be damaged by insertion of a speculum). Take a preliminary look at the cheek teeth by carefully retracting the tongue and cheek while shining a light into the mouth. Attempt to palpate the gingiva of the interdental space for enlargements or painful areas; the sharp points of the maxillary cheek teeth can be safely palpated by placing the fingers on the skin of the horse's cheek, adjacent to the upper cheek teeth (**FIGURE 3**). To inspect the mouth and perform procedures involving the cheek teeth, sedate the horse (e.g., with detomidine at 0.01 to 0.02 mg/kg IV). After waiting 5 minutes, insert a dental speculum. Support the horse's head at a sufficient height and use a bright light to facilitate the rest of the examination and any other procedures. With the speculum opened sufficiently, observe and palpate the cheek teeth for abnormalities. Frequently wetting the hands, arms, and instruments with water can reduce irritation to the patient's mouth, and wearing examination gloves can help minimize contamination of the clinician's skin with bacteria from the horse's mouth. Use of a dental mirror allows closer examination of the cheek teeth and gingiva. Use of an equine dental chart allows convenient recording of dental examination findings, dosages of medications administered, and treatments provided.

Routine Dental Conditions in Juvenile Performance Horses Incisors

It is not uncommon for weanlings and yearlings to sustain **trauma** to the incisors and adjacent bone, possibly resulting in avulsion

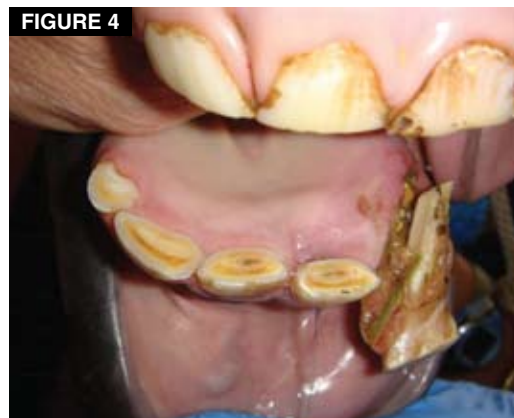

FIGURE 4
Frontal view of the occlusal portion of the mandibular incisors in a 2-year-old Quarter horse stallion. The lower-left intermediate deciduous incisor (Triadan 702) is avulsed. The four other lower incisor teeth (Triadan 701 and 801–803) appear normal. The lower-left lateral incisor (Triadan 703) is missing.

of or damage to the deciduous teeth as well as damage to the surrounding soft tissue and underlying permanent tooth buds (**FIGURES 4 THROUGH 6**). These traumatic injuries may result in the loss of one or more teeth or in abnormal eruption of teeth,¹⁰ possibly leading to malocclusion between the upper and lower incisor arcades. Overgrowth of an unopposed incisor may impede lateral movement of the mandible, affecting occlusion and chewing unless a portion of the unopposed tooth is shortened periodically. Overgrown incisors can be shortened without great difficulty as follows. Inject a sedative/analgesic (e.g., detomidine at 0.01 to 0.02 mg/kg IV or xylazine at 0.25 to 0.50 mg/kg IV). While supporting the sedated horse's head at an appropriate level, use a ruler to measure the area of tooth to be shortened, and mark it with a waterproof pen. Slide an incisor speculum (made of flexible polyvinylchloride pipe) into the interdental space, and secure it with an elastic cord around the poll to keep the incisor teeth apart. Use a hand file or power instrument to conservatively shorten the affected tooth/teeth (**FIGURE 7**). When motorized instruments are used, the tooth and burr should be cooled frequently with water irrigation, and the blade of the instrument should be cleaned frequently to reduce heat production and prevent thermal pulp injury.¹¹

Brachygnathia (parrot mouth) is an occasional malocclusion. The term *overjet* can

CriticalPoint

Veterinarians should understand skull anatomy, dental anatomy, and eruption times to most effectively perform dental examinations and procedures in horses.



FIGURE 5
A number of deciduous incisors are missing or have been damaged because of previous trauma in an approximately 30-month-old Quarter horse. The lower-central permanent incisors (Triadan 301 and 401) appear to be erupting normally.

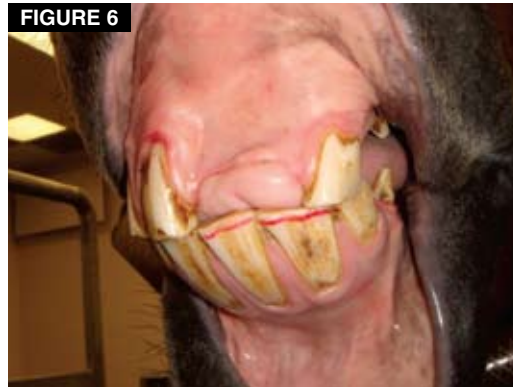

FIGURE 6
In this frontal view, upper incisor teeth are missing because of previous trauma. Over time, the unopposed lower incisors (Triadan 301 and 302) have become moderately overgrown. A length of crown (~4 mm) has been marked with a red water-proof pen to serve as a guide while shortening the unopposed teeth.

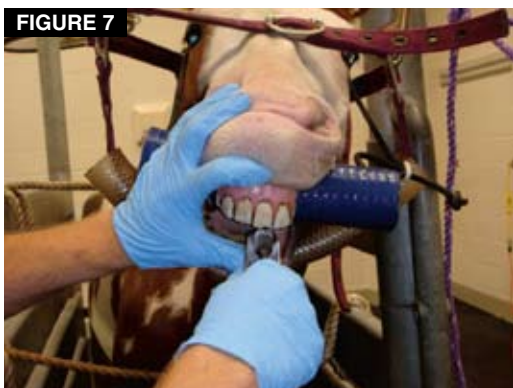


FIGURE 7
A motorized instrument is used to shorten overgrown incisors to form a more level chewing surface.

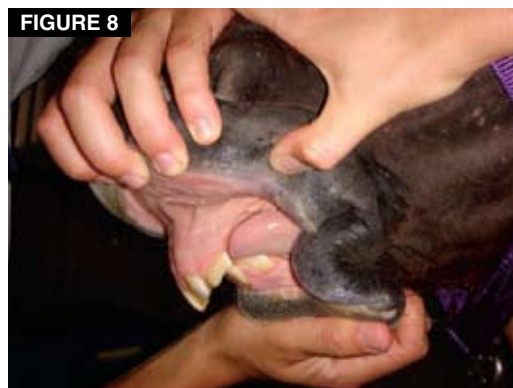

FIGURE 8
Severe overbite in a 5-year-old Quarter horse mare.

CriticalPoint

Sharp dental points on the cheek teeth may cause mucosal irritation and erosions on the cheeks or tongue due to repetitive contact.

be used to describe affected horses, in which the upper incisors project to some degree past the labial side of the lower incisors in a horizontal direction.¹² In severe cases, the upper incisors protrude past the lower teeth to an extent that allows the occlusal surface of the upper incisors to deviate ventrally below the occlusal surface of the lower incisors. This is called an *overbite*¹² (FIGURE 8). An overbite traps the lower incisors behind the upper incisors, limiting rostral movement and growth of the mandible and worsening the condition.^{7,12} With incisor overjet and overbite, the upper cheek teeth tend to be more rostral relative to the lower cheek teeth. As a result, affected horses tend to develop **sharp overgrowths** on the rostral aspect of the upper arcade and on the caudal aspect of the lower arcade

(FIGURES 9 AND 10). These sharp overgrowths can cause biting problems and limit rostral-caudal movement of the mandible.¹³ Incisor overjet has also been associated with the presence of excessive or exaggerated transverse ridges on the cheek teeth, which can further limit movement of the mandible.⁷

In affected horses, it is important to reduce the sharp overgrowths to promote normal movement of the mandible. Treatment includes periodic floating of sharp hooks and ramps of the cheek teeth, floating of excessive transverse ridges, and reducing the height of affected incisors.¹⁴ Horses should be adequately sedated during floating, which is facilitated by the use of appropriate head support, a full-mouth dental speculum, a bright light source, and up-to-date instrumentation.

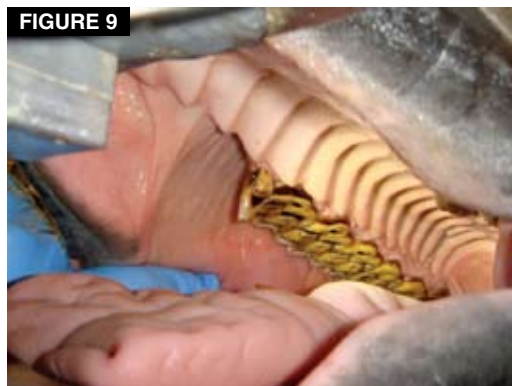

FIGURE 9
A large, sharp, rostral hook of the second premolar (Triadan 106) in a 5-year-old horse with incisor overjet. A wolf tooth (Triadan 105) is present.

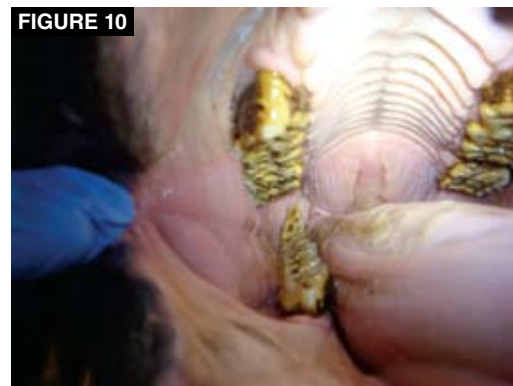

FIGURE 10
A tall, sharp hook on the caudal aspect of the last molar (Triadan 411).

CriticalPoint

A dental mirror is very useful, allowing close examination of the cheek teeth and gingiva.

When managing an overbite in a performance horse, it is important to remember that if the lower incisors are trapped behind the upper incisors, overgrown lower incisors may damage the mucosa of the hard palate and cause discomfort; additionally, overgrown upper incisors may contact the upper lip or cause painful injury if caught on a fence or other object.¹⁰ Therefore, horses with an overbite should have the overgrown upper and lower incisors shortened periodically. Horses with incisor overjet gradually develop a ventral curvature to the upper incisor occlusal margin (smile) that may hinder side-to-side movement of the mandible. Horses with this malocclusion can benefit from reduction of the overgrown incisors to form a more level incisor occlusal surface. For this procedure, prop open the mouth of the sedated horse and use a hand file or power instrument to conservatively reduce the height of the affected incisors (upper-central incisors and lower-corner incisors). It is important to remember that large overgrowths of permanent incisors should be shortened in stages to avoid acute exposure of the pulp chamber of the tooth.^{7,13,15}

In **prognathia (sow mouth, monkey mouth)**, which is the opposite of brachygnathia, the lower incisors protrude rostral to the upper incisors. If a horse has this condition, sharp hooks form on the rostral part of lower first cheek teeth and on the caudal part of the upper last molars. In horses with severe underbite, the upper incisors may become overgrown and damage the mucosa of the mandible behind the lower incisors. In these

cases, sharp areas and overgrowths of the incisors and cheek teeth should be inspected and floated to minimize biting problems and mucosal trauma associated with the underbite. Horses with malocclusions secondary to an incisor abnormality should be examined twice per year.

In horses with **retained deciduous incisors**, one or more deciduous incisors may fail to shed as the permanent incisor erupts.¹⁵ Discomfort may occur, resulting in clinical signs such as head tossing during eating, rubbing the incisors on fixed objects, quidding, biting problems, and swelling.^{8,15} Failure of the deciduous tooth to shed properly causes the permanent incisor to be displaced caudally and trapped behind adjacent incisors,¹³ possibly resulting in malocclusion of the permanent incisor arcade (**FIGURE 11**). Furthermore, the gap that develops between the retained deciduous tooth and the permanent tooth becomes packed with feed material, causing odor and irritating the gingiva. In most cases, the retained deciduous incisor cap and root remnant can easily be removed in a standing patient after administration of a sedative or analgesic (e.g., detomidine at 0.01 to 0.02 mg/kg IV or xylazine at 0.25 to 0.50 mg/kg IV) and either infiltration of a local anesthetic or a specific nerve block (e.g., a mental nerve block for lower teeth or an infraorbital nerve block for upper teeth). A small elevator can be used to pry, wiggle, and loosen the attachments of the tooth for its removal. Irritation and pain will result if the slim root portion of the deciduous incisor is not removed completely.¹³ If the deciduous incisor fractures during removal, the gingiva will need to be incised a short

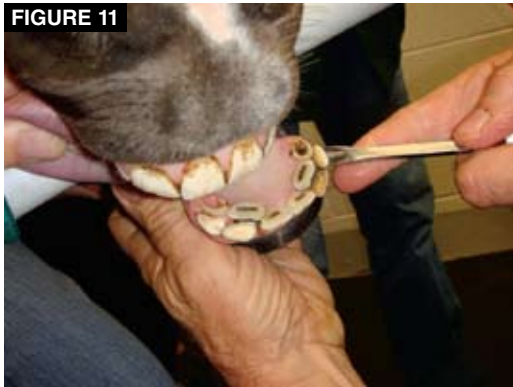

FIGURE 11
Retained deciduous incisors (Triadan 702, 703, 802, and 803) on the labial side of the corresponding permanent incisors. An elevator is positioned to indicate the location of retained deciduous incisor Triadan 703.

distance over the labial aspect of the root to expose and remove the entire fractured remnant.¹³ After removal of the retained deciduous incisor, the displaced permanent incisor should gradually drift into proper alignment. If it is crowded, slightly file the edge of the adjacent incisors to allow enough space. Aftercare is minimal, but tetanus prophylaxis is indicated after tooth extractions in horses.¹⁶

Canine Teeth

Although canine teeth cause few problems,¹⁵ erupting permanent canine teeth in stallions and geldings (rarely in mares) can irritate the eruption site on the mandible or maxilla and cause pain, biting problems, or abnormal behavior.^{6,17} In affected horses, swelling over the erupting canine tooth may become ulcerated.⁶ If painful or ulcerated swelling develops, the horse can be sedated and local anesthetic infiltrated over the erupting crown to remove a small section of gingiva. This can be accomplished using a forceps and scissors or using a scalpel to make a cruciate incision through the gingiva overlying the tooth.¹⁷ The rationale for this procedure is to facilitate tooth eruption through the gingiva. In performance horses, erupted canine teeth that become excessively sharp or that interfere with the bit can be shortened or blunted using a file or motorized instrument. To avoid damage to the pulp canal, it is recommended to reduce the crown of the canine tooth to no shorter than the level of the permanent corner incisor.¹⁷ Tartar buildup on canine teeth can be scraped and removed

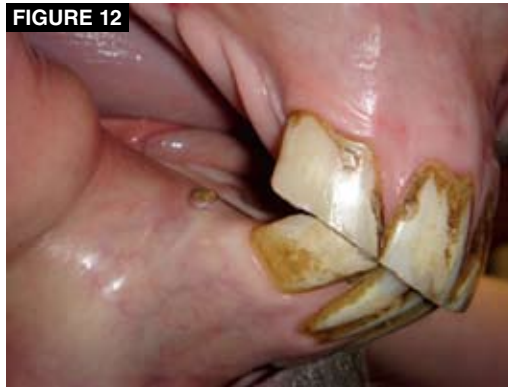

FIGURE 12
A vestigial canine tooth (Triadan 404) in the gingiva just caudal to the right-lower lateral incisor (Triadan 403) in a mare.

with a forceps, followed by polishing with a fine S-file. Canine teeth may erupt in mares, appearing as short, slender structures in the gingiva. Although these vestiges can be very sharp, canine teeth in mares generally do not require veterinary attention (FIGURE 12).

Cheek Teeth

Sharp dental points on the cheek teeth may cause mucosal irritation and erosion of the cheeks or tongue due to repetitive contact. Erosion of the cheek mucosa is more common in juvenile horses¹⁸; in one study, cheek erosion occurred with greater frequency in horses ridden with a bit and bridle compared with unriden horses.¹⁹ In addition, the tongue and interdental space of the mandible are vulnerable to injury from use of a bit.^{20,21} Problems that occur during performance, such as bit chewing, tail wringing, gaping the mouth, excessive head tossing, and ear pinning, have been associated with conditions causing oral pain.^{10,21} Because the skin and muscles of the face adhere tightly to the horse's skull, the buccal space along the upper cheek teeth is extremely narrow, especially in the caudal part of the mouth.²² Therefore, the cheeks are closely apposed to sharp points that develop along the buccal side of the upper cheek teeth. Consequently, erosion of the cheek mucosa in this area is not unusual in horses being examined for undesirable biting behavior (FIGURE 13). Sharp points of the lingual side of the lower cheek teeth may also irritate or erode the tongue.²³ Sharp overgrowths (i.e., hooks), such as those on the rostral part of the upper first cheek teeth or on the caudal aspect of the

CriticalPoint

Veterinarians should carefully palpate the upper and lower cheek teeth arcades to verify that floating has successfully removed sharp points and hooks.

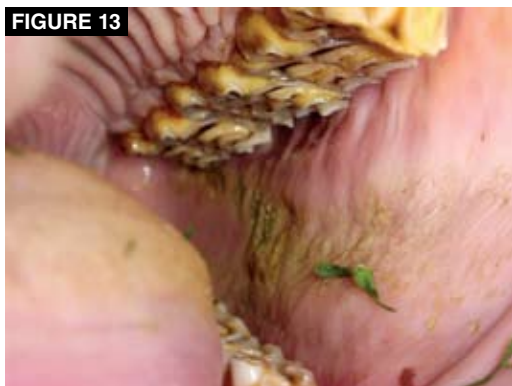

FIGURE 13
Extensive buccal erosions along the left cheek in a 5-year-old American Paint horse. The affected areas are stained with grass pigments.

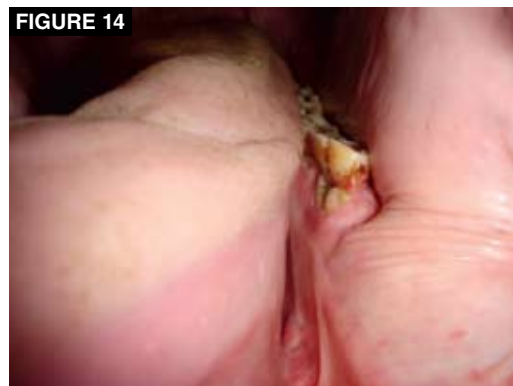

FIGURE 14
A deciduous premolar cap (Triadan 706) and the underlying erupting permanent premolar (Triadan 306) in an approximately 30-month-old Quarter horse.

last lower molars, may traumatize the cheeks or tongue; these sharp areas have been associated with biting problems and abnormal head carriage.²⁴

Sharp dental points require floating along the buccal side of the upper cheek teeth and the lingual side of the lower cheek teeth using hand instruments or motorized equipment. (To improve accuracy and decrease soft tissue trauma, my clinic prefers motorized instruments for most routine procedures.) Floating should be performed in an adequately sedated horse with the aid of a dental speculum. The horse's narrow oral opening, large tongue, and narrow buccal space create unique challenges for floating various teeth. Therefore, it is important to carefully palpate the upper and lower cheek teeth arcades to verify that floating has successfully removed sharp points and hooks. The rostral portion of the upper and lower first cheek teeth should also be floated and slightly rounded with a hand file or power instrument to help decrease irritation and pain as the bit presses the cheek against the premolars. This procedure is called *creating bit seats*.⁸

It is important to determine whether young performance horses have **wolf teeth** (Triadan '05). Most horses have one or two upper wolf teeth. Although debatable,²⁵ it is thought that these teeth may cause pain when they contact the bit or when the cheek mucosa presses against the sharp point of the tooth. Unerupted wolf teeth (blind or impacted wolf teeth) are thought to cause pain when the gingiva is compressed between the bit and the underlying tooth. Blind wolf teeth may be detected by palpating the interdental space, and radiogra-

phy may confirm their presence. Veterinarians commonly extract wolf teeth from juvenile horses. This is performed in standing, sedated horses and is facilitated by the use of a dental speculum and local anesthesia. After elevating the gingiva tissue around the circumference of the wolf tooth, the tooth is loosened and removed using an elevator to wiggle and pry the periodontal attachments from the tooth. Aftercare is usually minimal, although tetanus prophylaxis is advised after extractions. In my practice, horses commonly resume training 24 hours after wolf tooth extraction. Upper wolf tooth extraction sites are left open for healing and epithelialization; lower wolf tooth extraction sites can become contaminated with feed material and inflamed.^{6,8} Therefore, daily irrigation of lower wolf tooth extraction sites is recommended until granulation tissue has filled the alveolus. Gauze packing may also help minimize contamination of the site.⁸

Deciduous premolar caps that are loose or fractured or that fail to shed properly can irritate a horse^{7,23}; clinical signs of discomfort include loss of appetite, head shaking, biting problems, and chewing problems⁷ (**FIGURE 14**). Deciduous premolar caps can be safely extracted when a line of demarcation is visible between the cap and the erupting permanent tooth. The thin, wafer-like cap or remnant can be grasped with a forceps and rolled toward midline to facilitate removal (**FIGURE 15**). Alternatively, an elevator with a flattened end may be used to wiggle and pry the cap from its attachments (**FIGURE 16**). In either case, the cap and root spicules are removed without difficulty in most instances.

CriticalPoint

Deciduous premolar caps that are loose or fractured or that fail to shed properly can irritate a horse; clinical signs of discomfort include loss of appetite, head shaking, biting problems, and chewing problems.

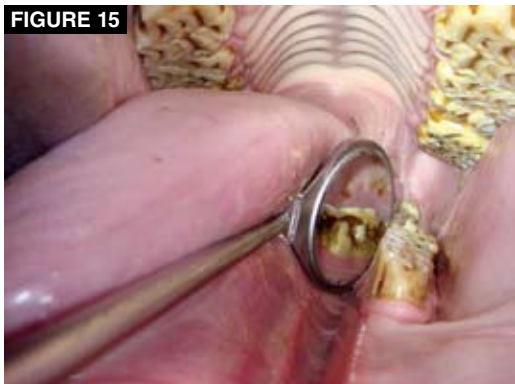

FIGURE 15
A retained cap (Triadan 708) is rotated toward the cheek in a 4-year-old Quarter horse. A dental mirror is used to help visualize the erupting permanent tooth (Triadan 308) and the retained cap. Buccal erosions are visible with the mirror.

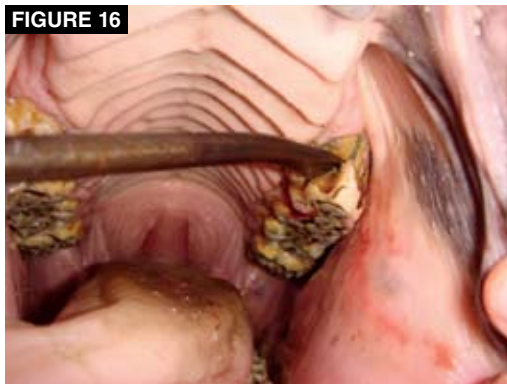

FIGURE 16
A deciduous premolar cap (Triadan 606) in a 3-year-old Quarter horse. A flat elevator is wedged into the gap between the cap and the underlying permanent tooth (Triadan 206).

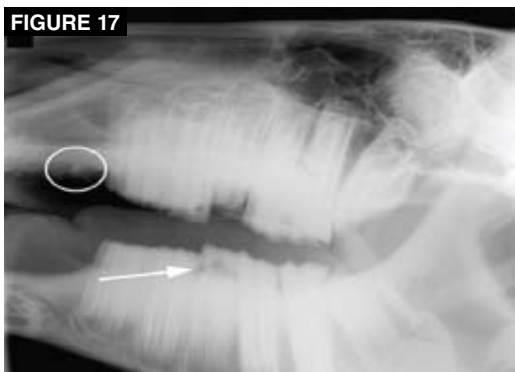

FIGURE 17
On this open-mouth, lateral radiograph, a thin mandibular premolar cap (arrow) can be distinguished from the underlying permanent cheek tooth in a 3-year-old horse. An unerupted upper wolf tooth (circle) is just rostral to the upper first cheek tooth.

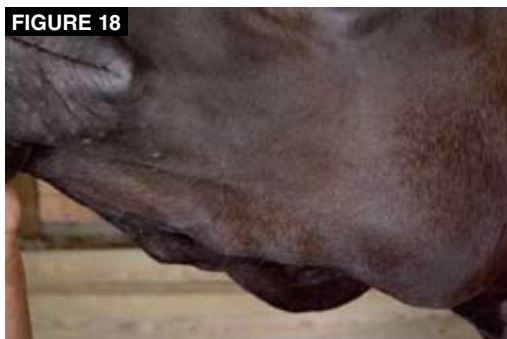

FIGURE 18
Firm, bony enlargements (called eruption cysts or eruption bumps) are present along the ventral margins of the mandibles in a 2-year-old Quarter horse stallion.

If a cap protrudes above adjacent teeth but a line of demarcation is not present or if the tooth cannot be removed with reasonable force, the cap should be floated until it is even with adjacent teeth.²⁶ Because the crown of the deciduous premolar cap closely resembles the crown of the permanent tooth, it may be very difficult to determine whether a premolar cap has been shed. If this must be determined, an open-mouth, lateral oblique radiograph can be very helpful. A premolar cap can usually be identified on a radiograph as a short, thin slice of tooth situated over the underlying permanent premolar (FIGURE 17).

Eruption cysts are bony enlargements that can be observed in juvenile horses on the ventral aspect of the mandible and on the dorsolateral aspect of the maxilla (FIGURE 18).

These cysts normally result from mild compression from erupting permanent premolars at 3 and 4 years of age; the cysts regress over the next 1 to 2 years.^{7,27,28} In general, eruption cysts are not as noticeable on the maxilla because of overlying soft tissue.²⁴ In some cases, crowding and compression (impaction) of the erupting permanent tooth may cause an unusually large, warm, painful swelling of the maxilla or mandible²⁸ (FIGURE 19). If this develops, examine the horse for retained deciduous premolars.²⁴ Radiography should also be used to evaluate the dental and bone structures associated with large eruption cysts. On radiography, eruption cysts of the mandible appear as smooth-bordered, periapical lucencies with sclerotic margins²⁹ (FIGURE 20). It is important to remember that blood-borne bacteria can invade inflamed dental tissue associated with eruption cysts, resulting in infection

CriticalPoint

Eruption cysts are bony enlargements that can be observed in juvenile horses on the ventral aspect of the mandible and on the dorsolateral aspect of the maxilla.

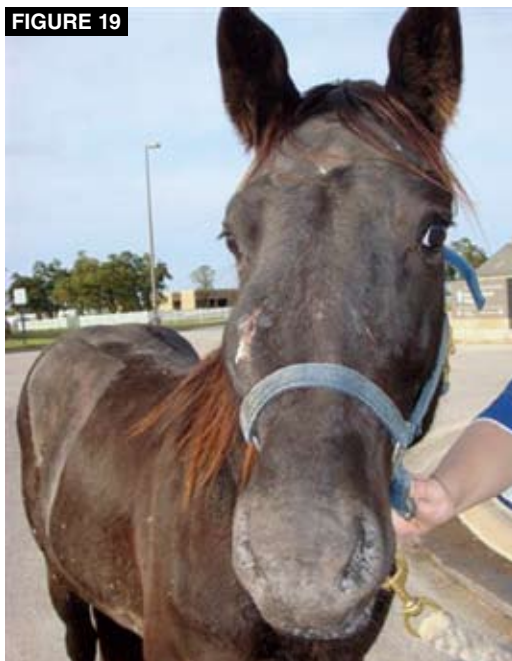

FIGURE 19
An enlarged, painful eruption cyst of the right maxilla with a draining tract in a 3-year-old mare.

of the pulp and the periapical region through a process called *anachoresis*.^{7,30}

Conclusion

Dental problems may cause discomfort to juvenile horses during performance. In young horses, dental conditions such as sharp den-

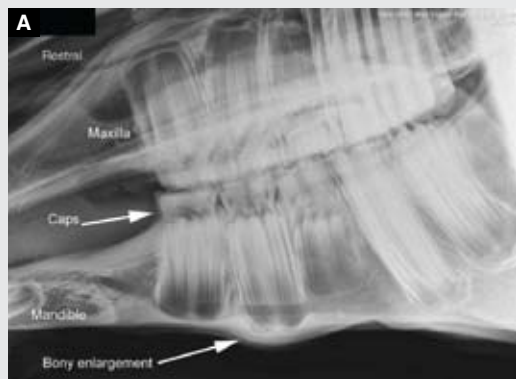tal points, erosions of the cheeks and tongue, and loose or damaged premolar caps have been associated with biting problems and can negatively influence performance. Unopposed incisors become overgrown, possibly impeding movement of the mandible. Likewise, overbite and underbite limit mandibular mobility, resulting in sharp dental overgrowths and malocclusion of the incisors and cheek teeth. Retained deciduous incisors can cause discomfort and abnormal eruption of underlying permanent teeth. Eruption cysts normally arise during cheek tooth eruption but may become enlarged and painful. Equine veterinarians should know skull anatomy, dental anatomy, and tooth eruption times to effectively perform dental examinations and procedures on young horses. Through dental examination of juvenile horses, equine veterinarians can identify and alleviate several significant dental conditions and provide clients with important information regarding the overall well-being of their horses. 🐾

Acknowledgments

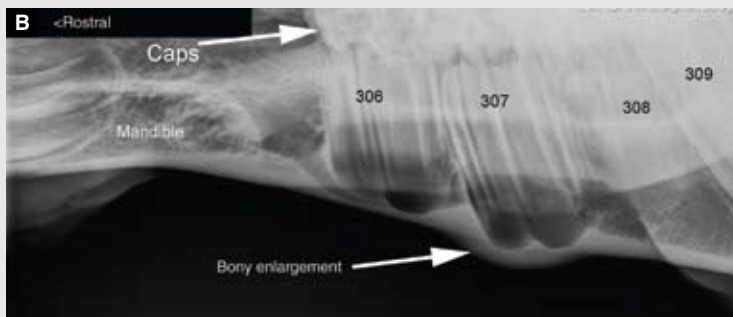
The author acknowledges the following individuals at the College of Veterinary Medicine at Texas A&M University for their assistance in preparing this article: Michael Walker, DVM, Department of Large Animal Clinical Sciences; Kyle Westfall, veterinary technician, Veterinary Medical Teaching Hospital; and Betsy McCauley, veterinary radiologic technologist, Veterinary Medical Teaching Hospital.

FIGURE 20

Radiography of eruption cysts.



This lateral radiograph of the mandible and maxilla of a 2-year-old Quarter horse shows caps on premolars 2, 3, and 4 (Triadan '06, '07, and '08) in the upper and lower jaws and mild cortical thickening of the mandible ventral to premolar 3 (Triadan '07).



This oblique lateral radiograph of the right mandible shows smooth-bordered periapical lucency and cortical bony enlargement involving premolar 3 (Triadan 307) due to a slight eruption cyst.

References

- Nickel R, Schummer A, Seiferle E. *The Viscera of Domestic Mammals*. 2nd ed. Philadelphia: Springer-Verlag; 1979:95.
- Sisson S, Grossman JD. *Anatomy of Domestic Animals*. 4th ed. Philadelphia: WB Saunders; 1953.
- Floyd MR. The modified Triadan system nomenclature for veterinary dentistry. *J Vet Dent* 1991;8(4):18-19.
- Martin MT. *Guide for Determining the Age of the Horse*. 7th ed. Lexington, KY: AAEP; 2007.
- Dixon PM. Dental anatomy. In: Baker GJ, Easley J, eds. *Equine Dentistry*. 2nd ed. Philadelphia: Elsevier; 2005:25-48.
- Easley KJ. Equine canine and first premolar (wolf) teeth. *Proc AAEP* 2004;50:13-18.
- Dixon PM, Dacre I. A review of equine dental disorders. *Vet J* 2005;169:165-187.
- Easley KJ. Corrective dental procedures. In: Baker GJ, Easley J, eds. *Equine Dentistry*. 2nd ed. Philadelphia: Elsevier; 2005:221-248.
- Brown SL, Shaw DJ, Dixon PM, Arkins S. Occlusal angles of cheek teeth in normal horses and horses with dental disease. *Vet Rec* 2008;162:807-810.
- Scrutchfield L, Schumacher J. Examination of the oral cavity and routine dental care. *Vet Clin North Am* 1993;9(1):123-131.
- Baker GJ, Allen ML. The use of power equipment in equine dentistry. *Proc AAEP* 2002:438-442.
- Glossary of equine dental terminology. In: Baker GJ, Easley J, eds. *Equine Dentistry*. 2nd ed. Philadelphia: Elsevier; 2005:329-346.
- Johnson TJ, Porter CM. Common disorders of incisor teeth and treatment. *Focus Dent Proc AAEP* 2006:32-38.
- Easley J. Basic equine orthodontics. In: Baker GJ, Easley J, eds. *Equine Dentistry*. 2nd ed. Philadelphia: Elsevier; 2005:249-266.
- Dixon PM, Tremaine WH, Pickles K, et al. Equine dental disease part 1: a long-term study of 400 cases: disorders of incisor, canine and first premolar teeth. *Equine Vet J* 1999;31(5):369-377.
- Tremaine WH, Lane JG. Exodontia. In: Baker GJ, Easley J, eds. *Equine Dentistry*. 2nd ed. Philadelphia: Elsevier; 2005:267-294.
- Caldwell LA. Canine teeth in the equine patient. *Focus Dent Proc AAEP* 2006:47-55.
- Allen TE. Incidence and severity of abrasions on the buccal mucosa adjacent to the cheek teeth in 199 horses. *Proc AAEP* 2004:31-36.
- Tell A, Egenvall A, Lundström T, Wattle O. The prevalence of oral ulceration in Swedish horses when ridden with bit and bridle and when unriden. *Vet J* 2008;178(3):405-410.
- Manfredi J, Clayton HJ, Rosenstein D. Radiographic study of bit position within the horse's oral cavity. *Equine Comp Exerc Physiol* 2005;3:195-201.
- Bennet DG. An overview of bits and biting. *Focus Dent Proc AAEP* 2006:181-195.
- Orsini PG. Oral cavity. In: Auer JA, ed. *Equine Surgery*. Philadelphia: WB Saunders; 1992:218-305.
- Stubbs RC. Dentistry of equine cheek teeth. *Proc AAEP* 2004; 50:1-6.
- Dixon PM, Tremaine WH, Pickles K, et al. Equine dental disease part 2: a long-term study of 400 cases: disorders of development and eruption and variations in position of the cheek teeth. *Equine Vet J* 1999;31(6):519-528.
- Carmalt JL. Evidence-based equine dentistry: preventive medicine. *Vet Clin Equine* 2007;23:519-524.
- Linkous MB. Dental conditions affecting juvenile performance horses. *Proc AAEP Dent Focus* 2006:212-220.
- Dixon PM. Dental anatomy. In: Baker GJ, Easley KJ, eds. *Equine Dentistry*. Philadelphia: WB Saunders; 1999:3-28.
- Dacre IT. Equine dental pathology. In: Baker GJ, Easley J, eds. *Equine Dentistry*. 2nd ed. Philadelphia: Elsevier; 2005:91-109.
- Gerard MP, Wotman KL, Komaromy AM. Infections of the head and ocular structures in the horse. *Vet Clin Equine* 2006;22:591-631.
- Dixon PM, Tremaine WH, Pickles K, et al. Equine dental disease part 4: a long-term study of 400 cases: apical infections of cheek teeth. *Equine Vet J* 2000;32(3):182-194.

3 CE
CREDITS

CE TEST 1 This article qualifies for 3 contact hours of continuing education credit from the Auburn University College of Veterinary Medicine. Subscribers may take individual CE tests online and get real-time scores at CompendiumEquine.com. Those who wish to apply this credit to fulfill state relicensure requirements should consult their respective state authorities regarding the applicability of this program.

- When do the deciduous premolars normally erupt in horses?**
 - at birth or shortly thereafter
 - at 2 years of age
 - at 3 years of age
 - at 4 years of age
- The difference in width between the upper and lower jaws is called**
 - isognathia.
 - brachygnathia.
 - prognathia.
 - anisognathia.
- Brachygnathia is also known as**
 - sow mouth.
 - monkey mouth.
 - parrot mouth.
 - none of the above
- Retained deciduous incisors**
 - may be associated with discomfort.
 - cause caudal displacement of the erupting permanent incisors.
 - can be removed in a standing patient.
 - all of the above
- Canine teeth**
 - are usually problematic in mares and should be removed.
 - may irritate the eruption site.
 - are synonymous with wolf teeth.
 - none of the above
- In regard to the cheek teeth, sharp dental points and overgrowths**
 - may traumatize the cheeks or tongue.
 - have been associated with biting problems.
 - require floating.
 - all of the above
- Deciduous premolar caps**
 - may cause discomfort.
 - do not occur in fillies and mares.
 - are also known as *wolf teeth*.
 - none of the above
- Eruption cysts**
 - are not detectable with radiography.
 - are associated with eruption of permanent premolars.
 - do not occur on the maxilla.
 - all of the above
- Wolf teeth may**
 - cause pain due to bit contact.
 - not be present in all of the dental arcades.
 - not erupt.
 - all of the above
- In regard to dental examination,**
 - wetting the hands and instruments can reduce irritation to the horse's mouth.
 - wearing examination gloves helps minimize contamination of the clinician's skin.
 - a bright light source facilitates most procedures.
 - all of the above