

# Examination of the oral cavity in equine dentistry



Tilman Simon  
Dr. med. vet.  
Cert. vet. Dent.  
Equine veterinary dentist (SVA)

Buerg 27  
D- 83627 Warngau  
Germany

[www.pferdedental.de](http://www.pferdedental.de)

# Tegernsee



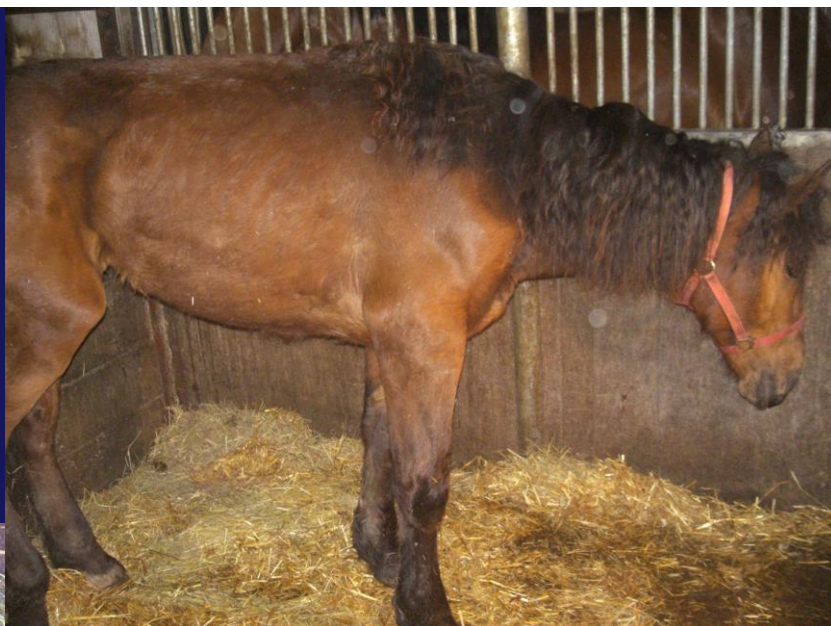## Anamnesis

- Expectations of the owner / Reasons for the examination
- Supposed age of the horse
- Breed / Signalement
- Sex
- Use of the patient and holding conditions
- Former diseases and premedication
- Former dental treatments
- Vaccinations (Tetanus?)
- Feeding and access to water

## Examination of the unsedated horse and its environment

- Behaviour and hierarchic status in the group
- Real environmental conditions
- Access to water and food
- Nutritional condition
- Foot and hair
- Condition of the bit and the equipment

Examination of  
the unsedated  
horse and its  
environment



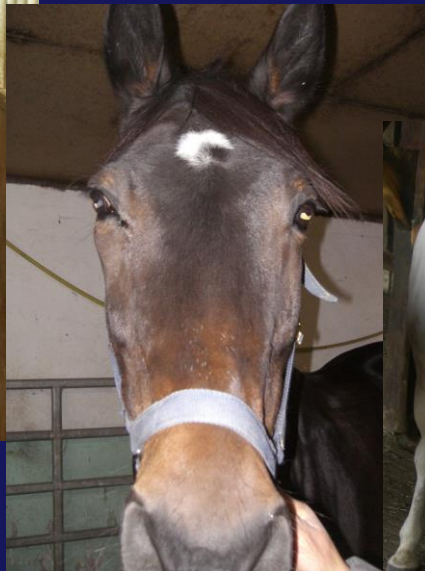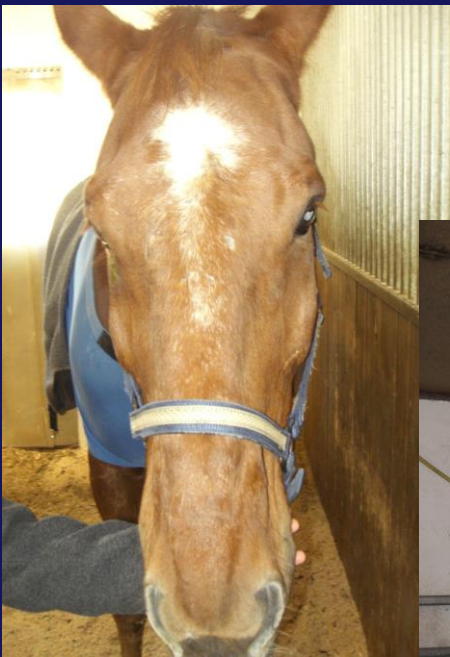# Equipment



## Inspection of the head

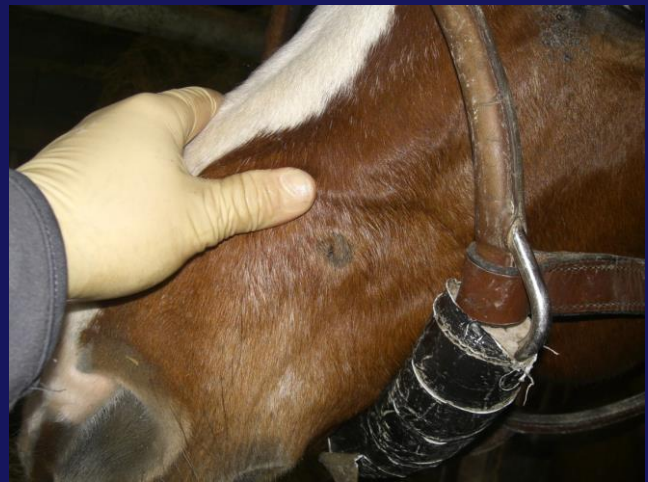

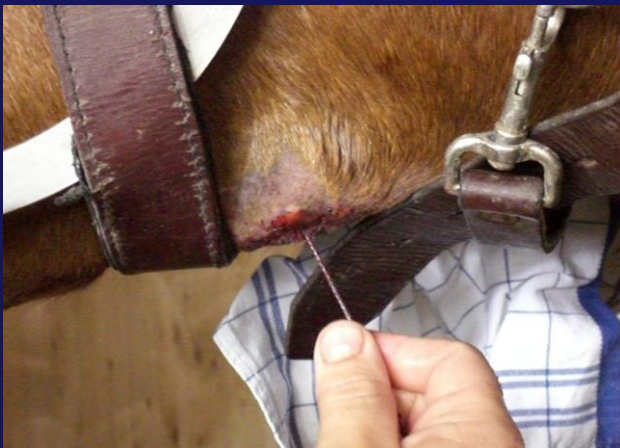
- Symmetry of the head
  - Headbones
  - Temporomandibular joints (TMJ)
  - Masticatory muscles
- Scars
- Nasal discharge
- Salivation / viscosity of the saliva
- Lips and tongue
- Mandibular bumps/ maxillary bumps
- Fistulae

## Asymmetry of head bones

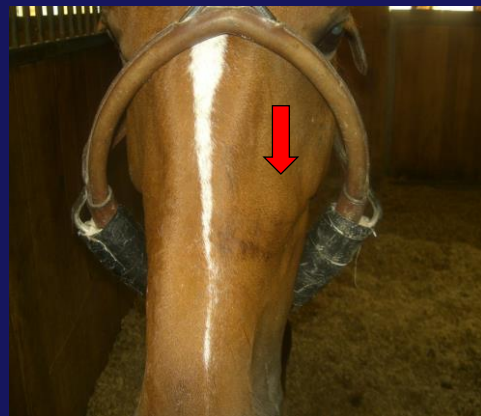
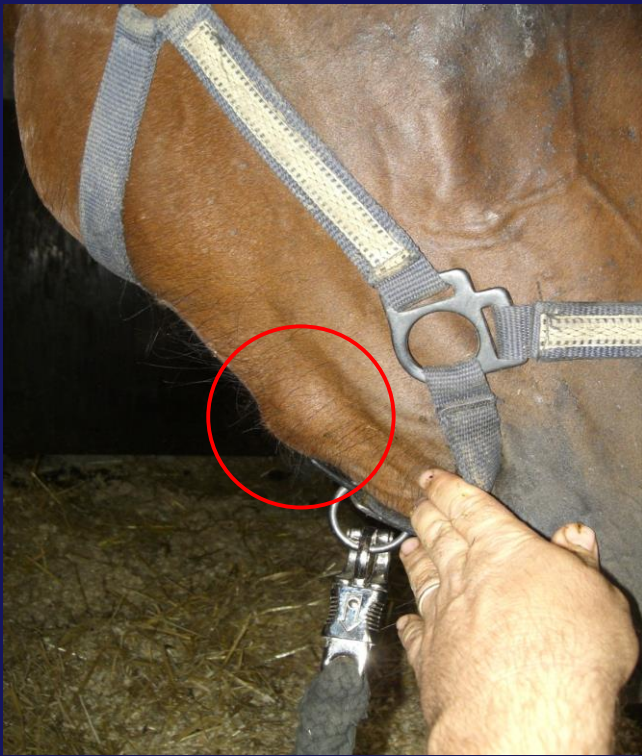


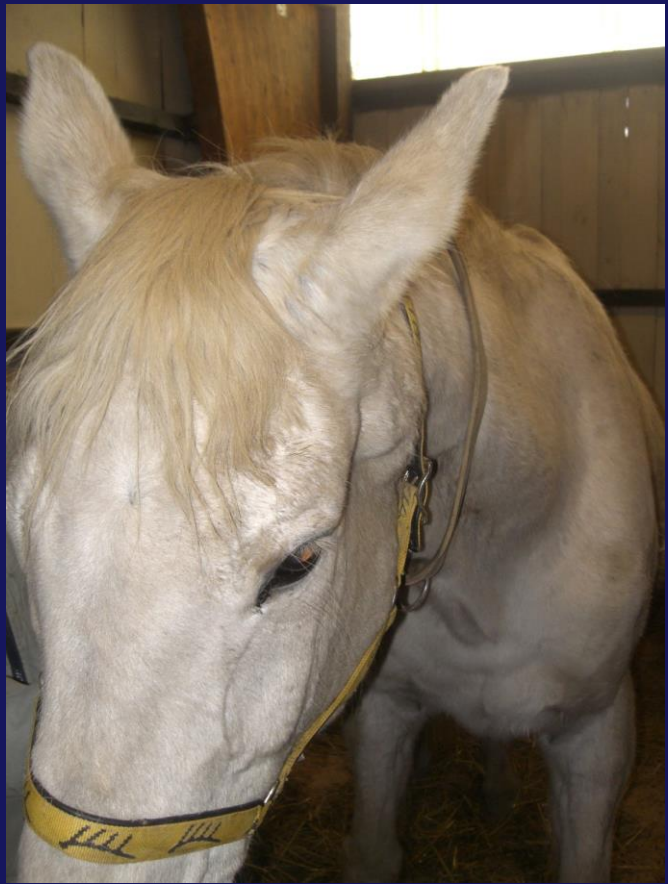Fistula,  
Unilateral discharge,  
Scar

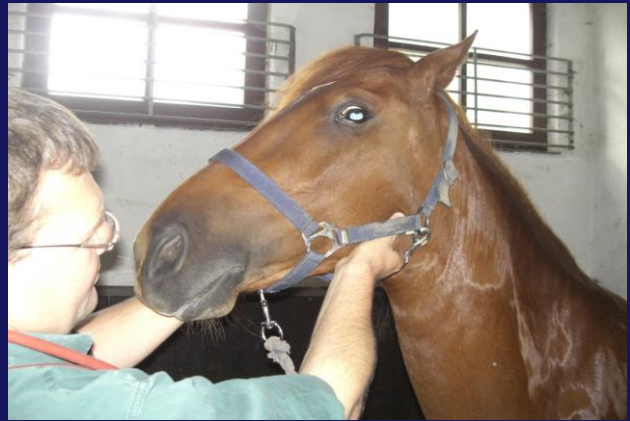
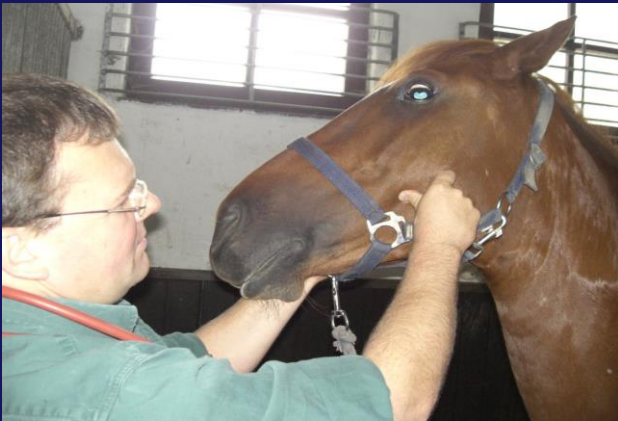
## Mandibular and maxillary bumps

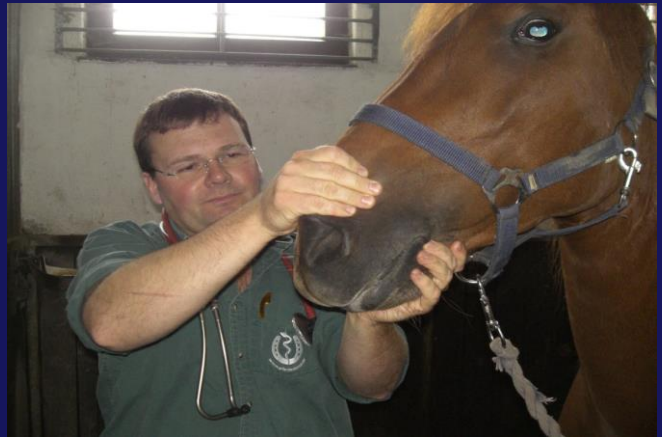

***Not every swelling  
is tooth related!***

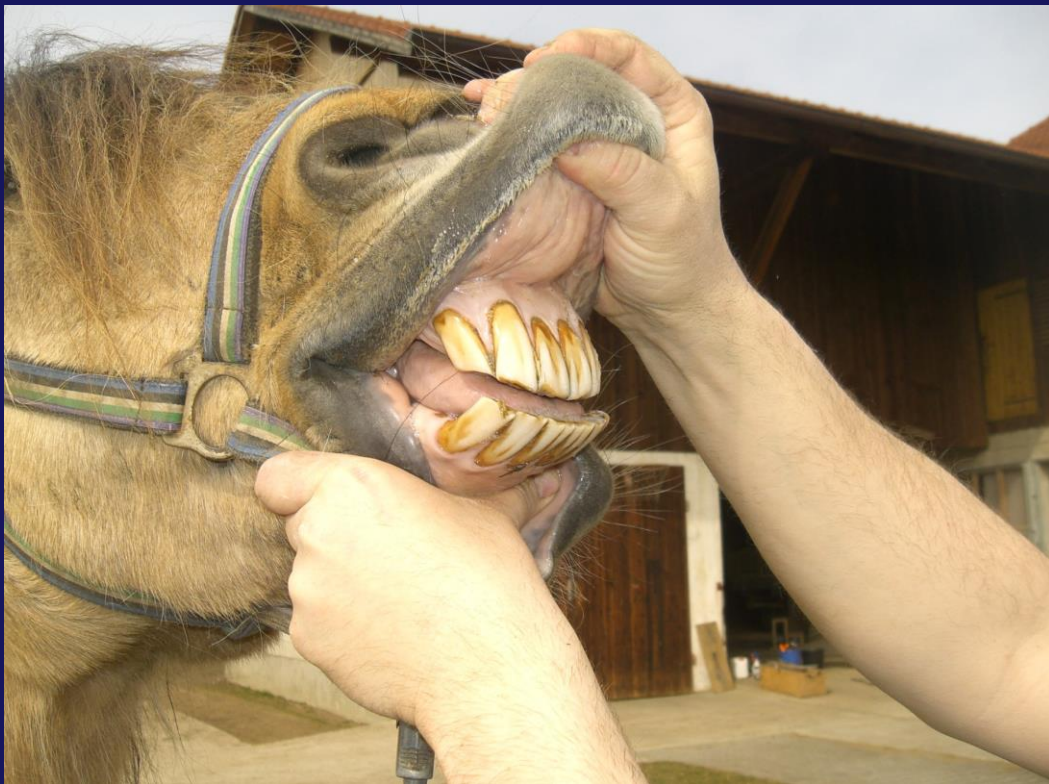




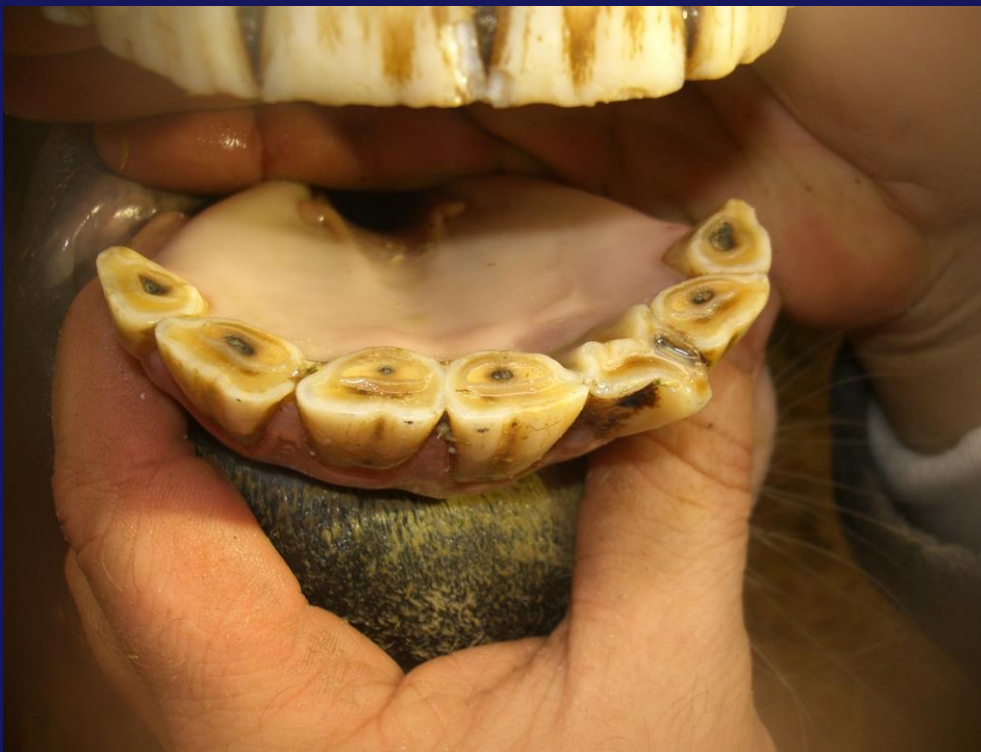Palpation of the unsedated horse



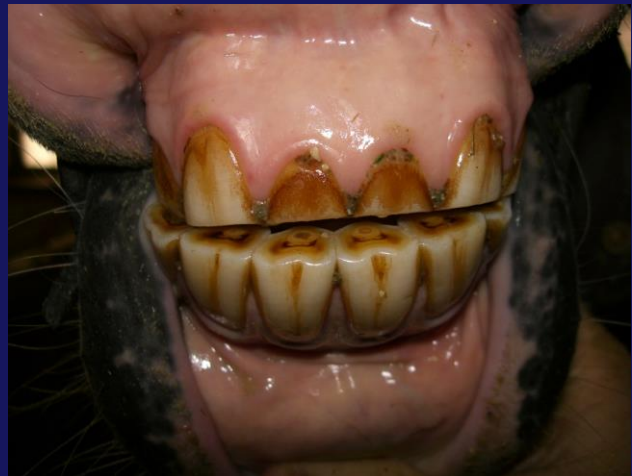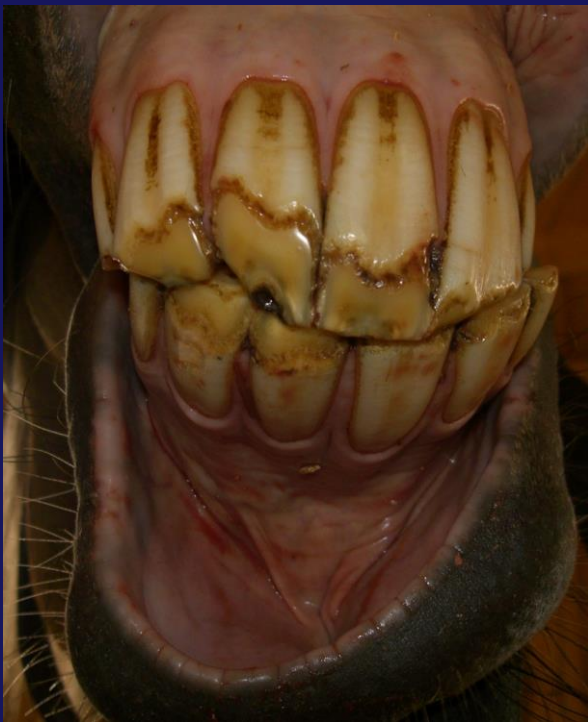## Inspection of incisors on the unsedated horse



## Incisors: Polyodontia

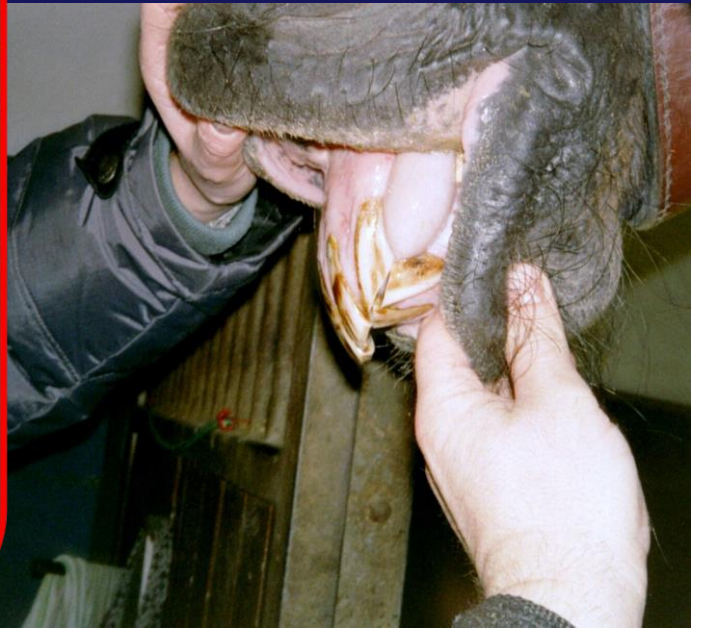
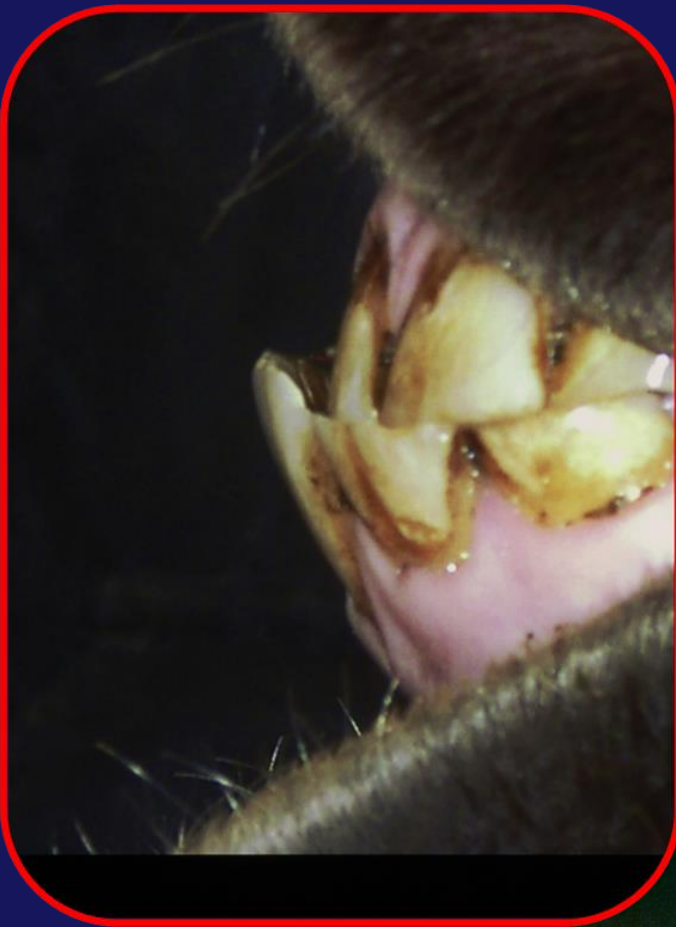
**Incisors:**  
Horse vices such as wind sucking and  
crib-biting



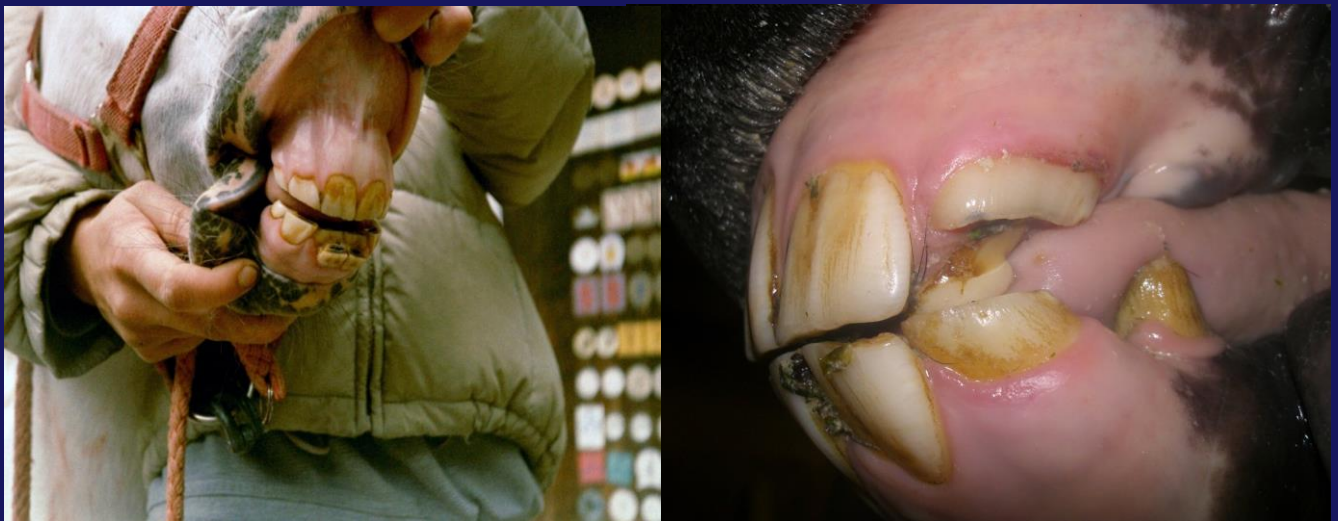
## Incisors:

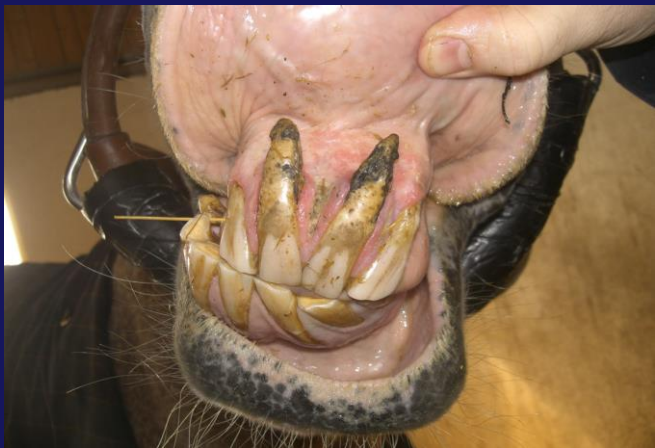
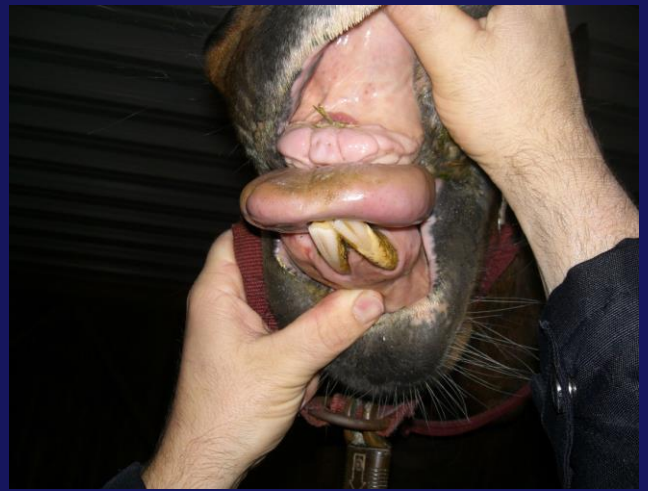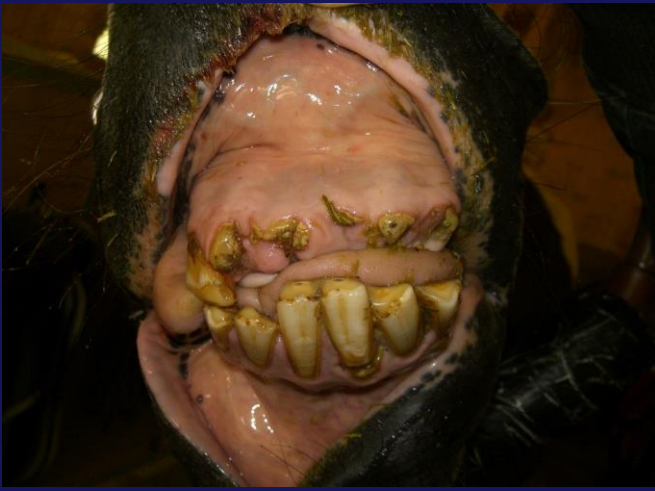
Underbite/ underjet  
and overbite/overjet





## Retention of deciduous incisors

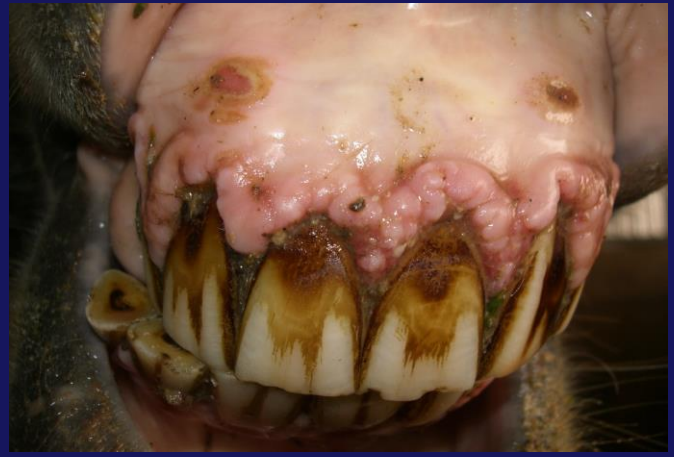
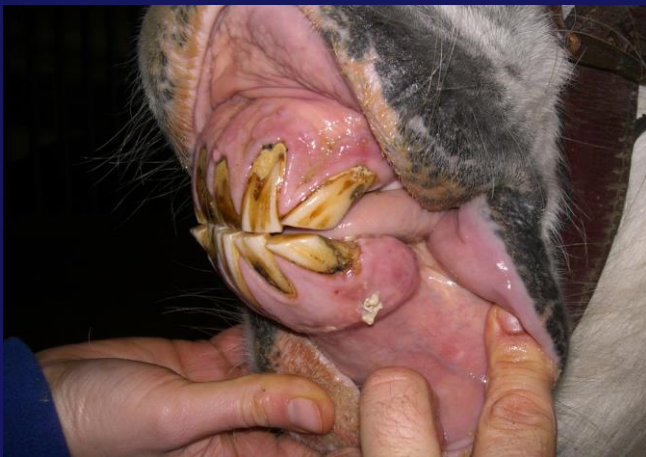
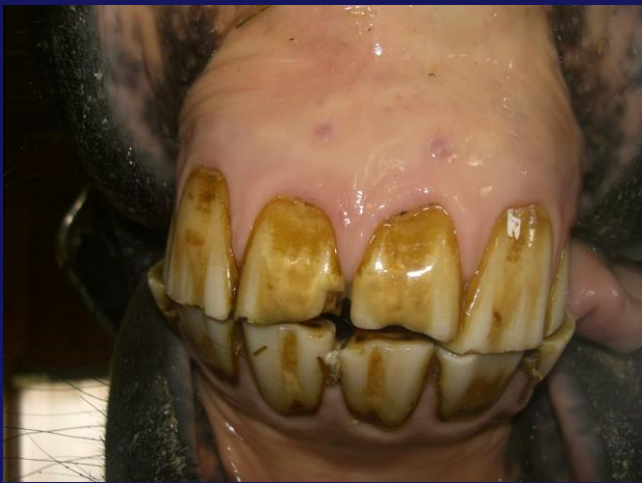

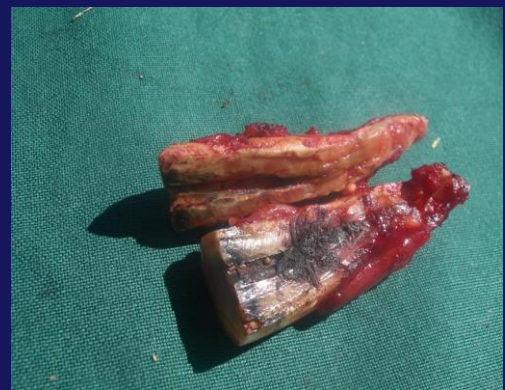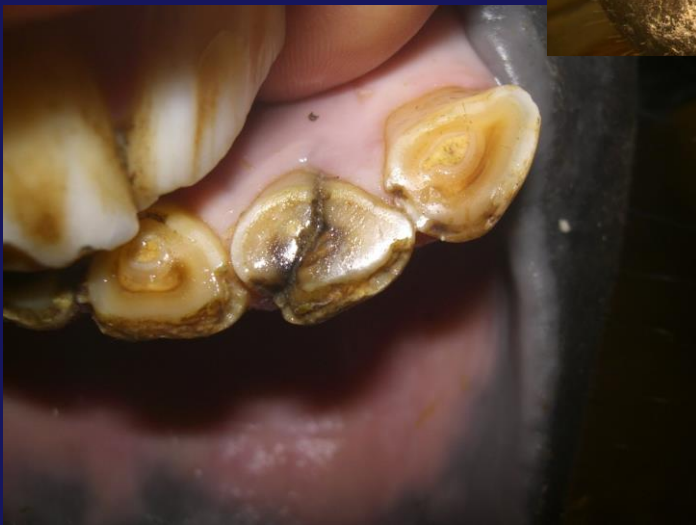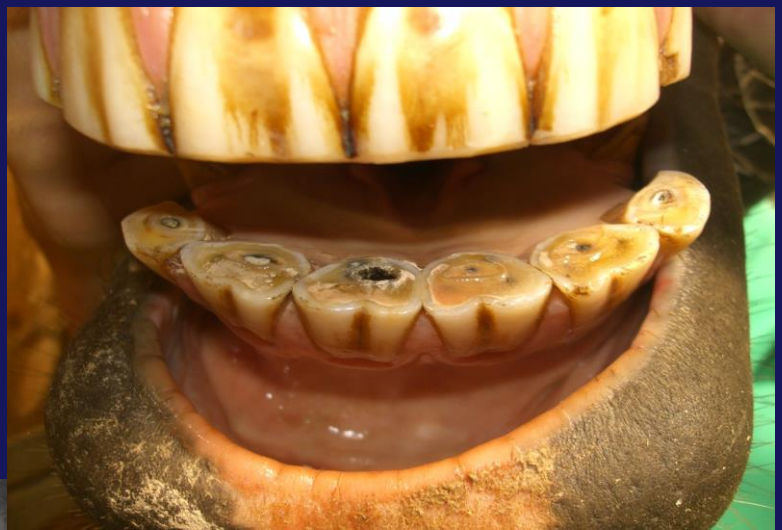Incisors of the geriatric horse

## Gingiva around the incisors

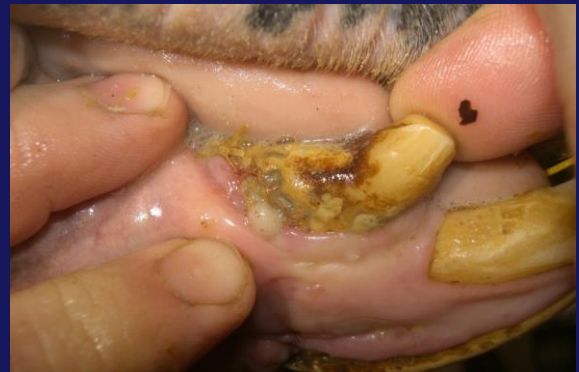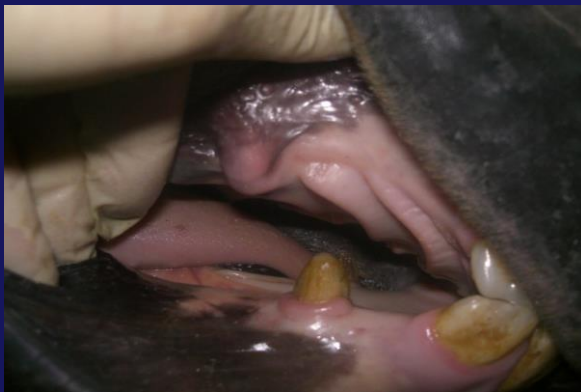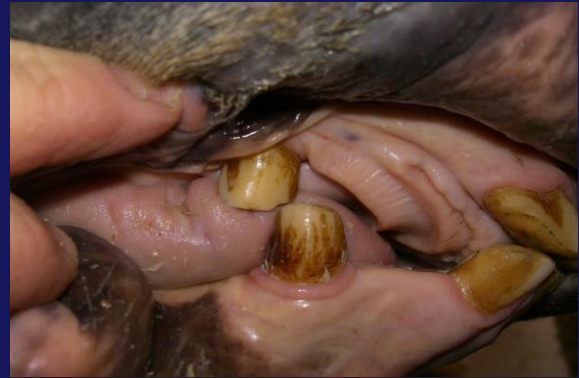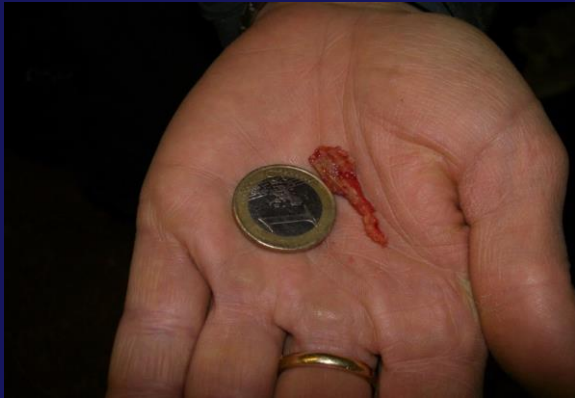- Fistulation at the apex
- Gingivitis
- EOTRH /Equine odontoclastic tooth resorption and hypercementosis



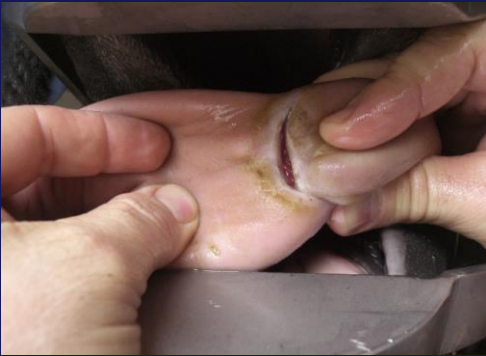**Incisors:**  
Inspection of the  
tables



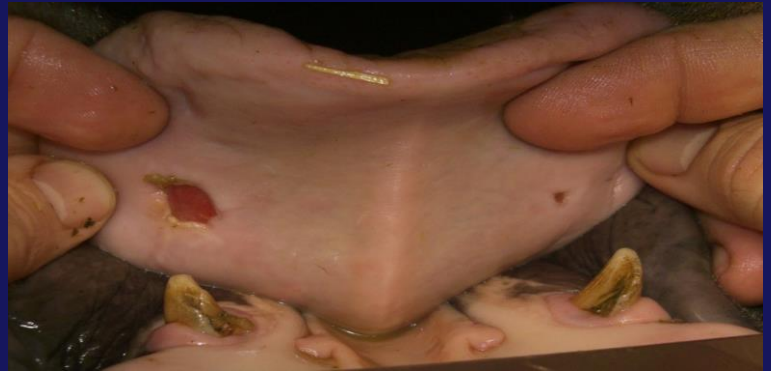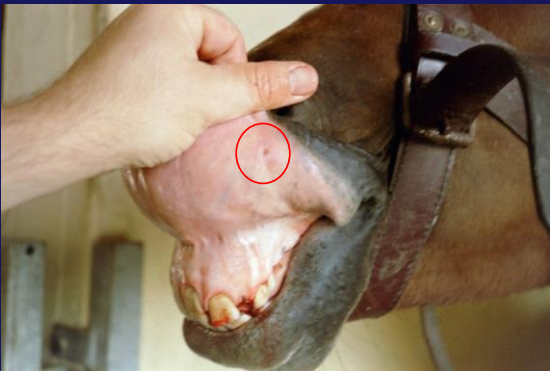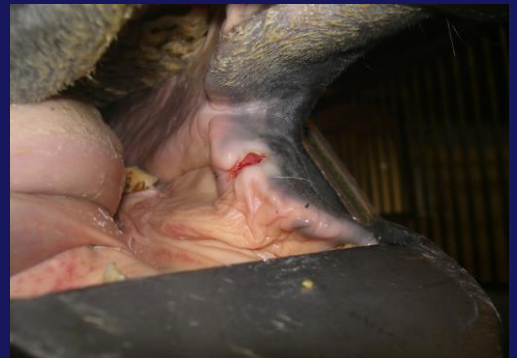## Inspection and palpation of the bars and the canines



## Inspection of the oral cavity in the unsedated horse:



The lips and the tongue



## Inspection of the oral cavity in the unsedated horse





...empty  
mouth  
please...



## Findings in the mouth of an unsedated horse

- Age and conditions of detention
- Character and manners of the horse
- State of general health
- Temporomandibular joints masticatory muscles and head bones
- Incisors (number, clinical integrity, capacity to hold the mouthgag)
- Lips, gingiva and mucous membranes
- Canines and the bars
- Tongue and its mobility
- First impression of the cheek teeth and surrounding tissues
- Halitosis and quality/ quantity of the saliva

## Sedation- why?

- Never put a mouth gag on an unsedated horse: deadly hazard!
- Exact inspection of all aspects of the teeth
- No compromise in diagnostics
- No compromise in treatment
- Less stressful for the patient
- Less stressful for the vet - and the owner



## **Sedation: Dosage i.v.**



Detomidine: 20-40 $\mu$ g/ kg  
Butorphanole: 0,008- 0,01 mg/ kg

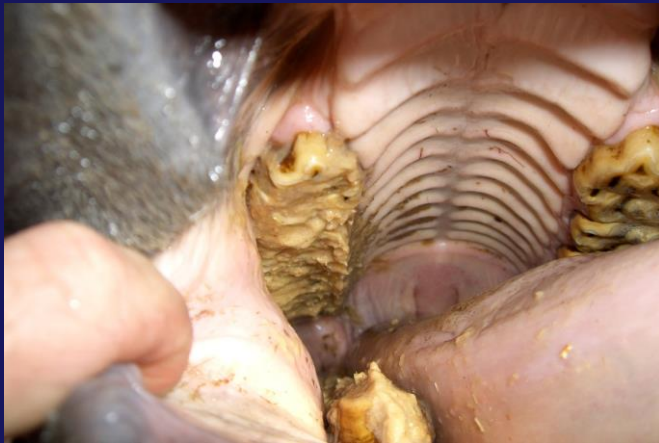
Undesired effects of sedation:

- Bradycardia
- Interrupted peristaltics
- Diuresis after approx. 1 hour
- Push forward
- Swallowing reflex is restricted
- Transpiration
- Hypersensitivity of the skin: danger of kicking!
- Doping!

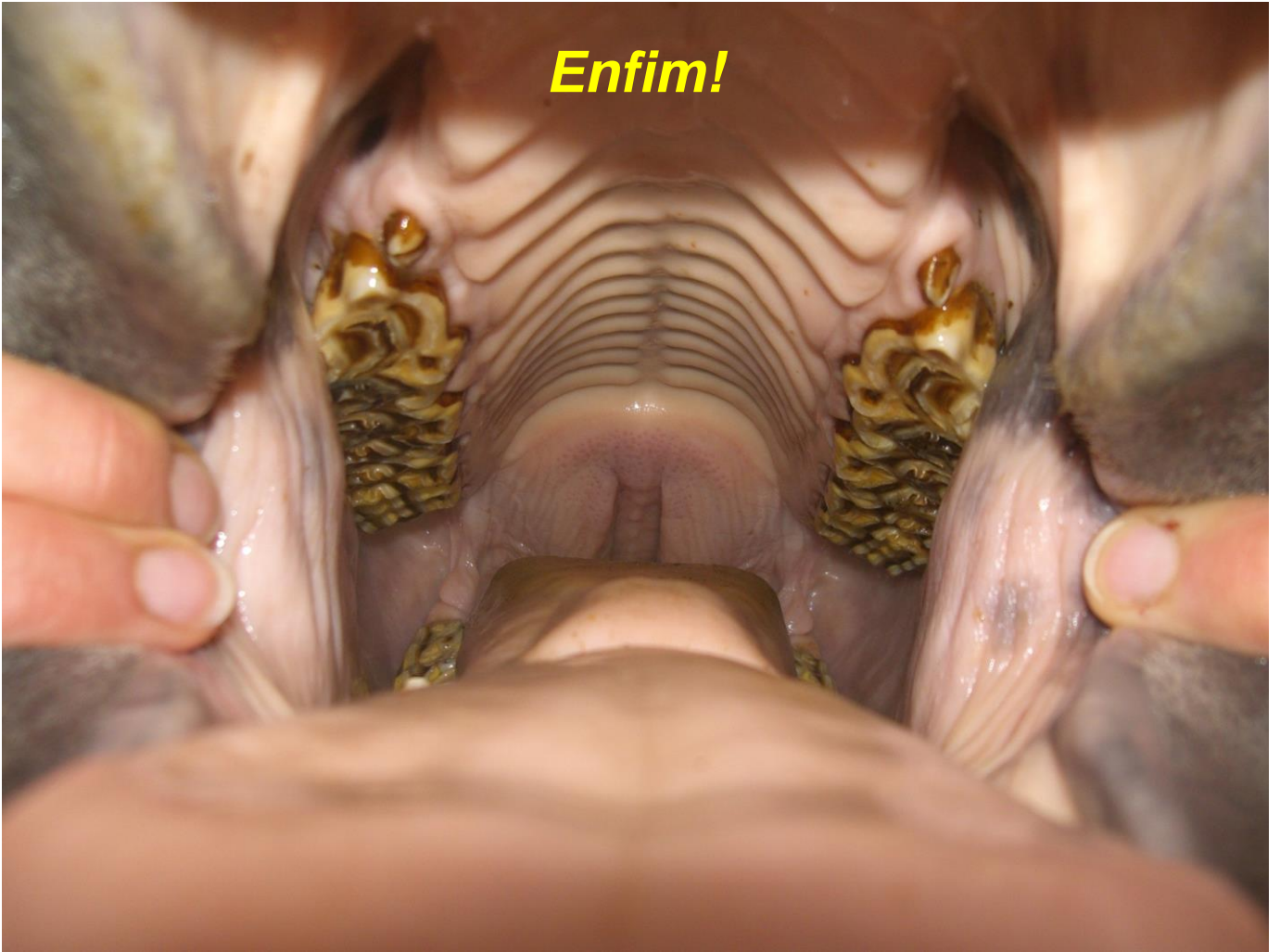
## Inserting the mouth gag

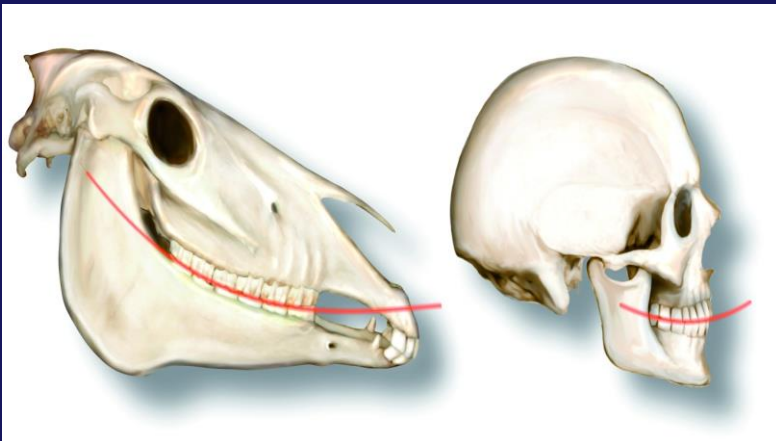


## Flushing the mouth



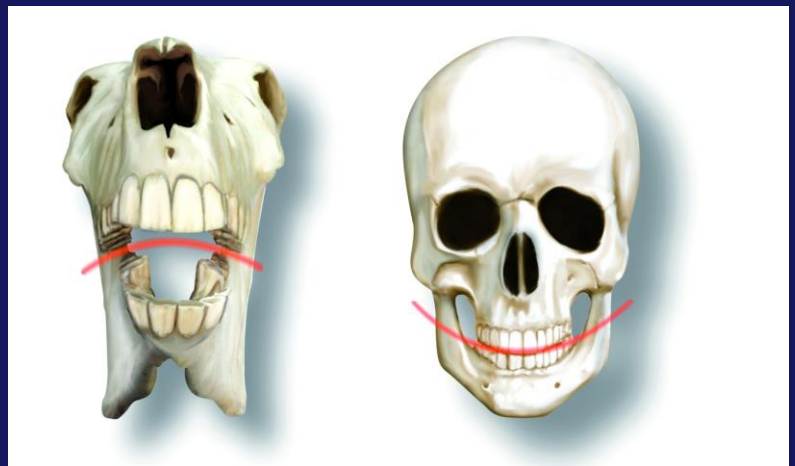
*Enfim!*



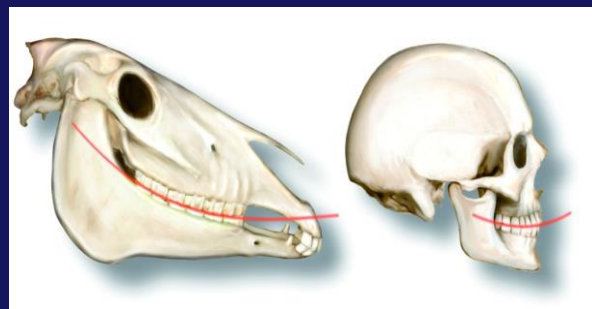
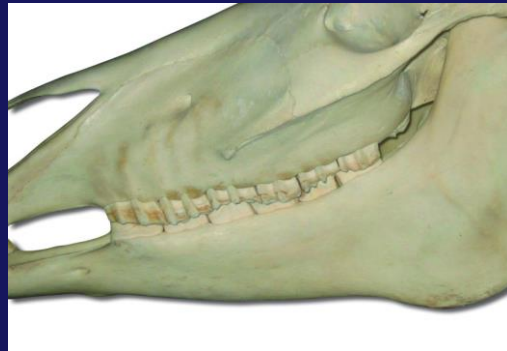
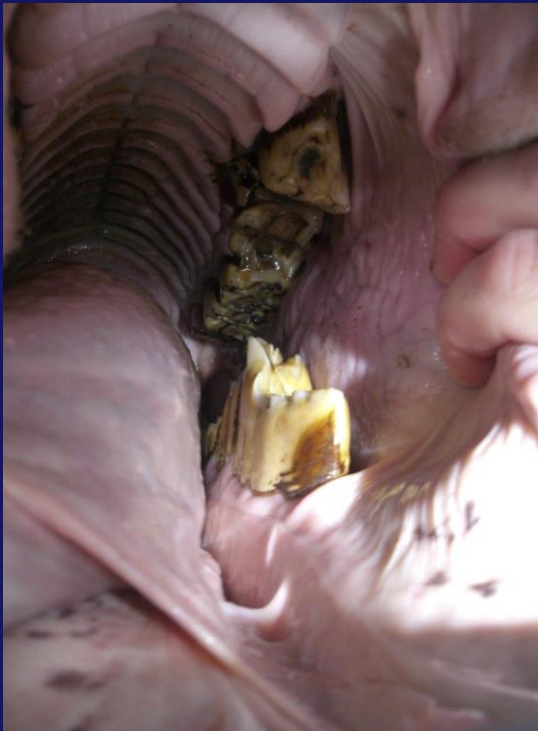
Dental arcade  
(curve of spee)  
and table angles of the  
cheek teeth  
(curve of Wilson)

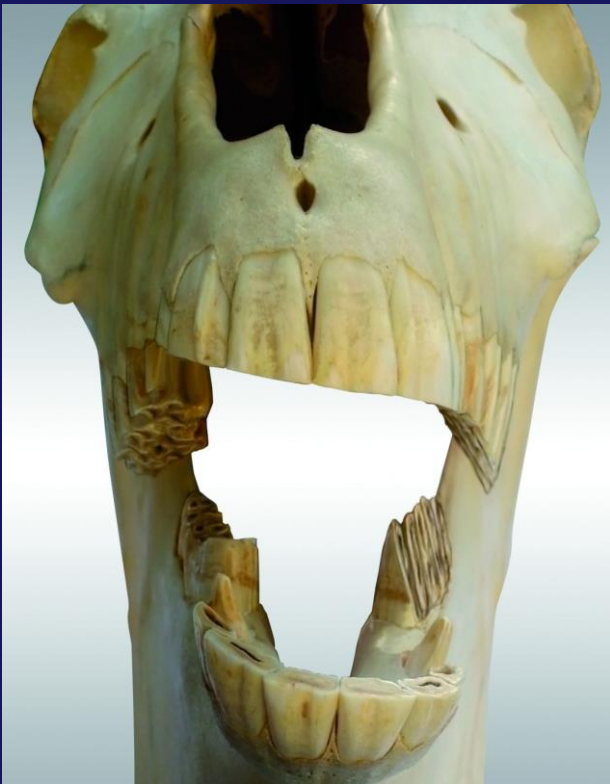From: „Praxisleitfaden Zahn- und  
Kiefererkrankungen des Pferdes“  
by T. Simon, I. Herold and H.  
Schlemper. Parey Editors,  
Stuttgart 2009



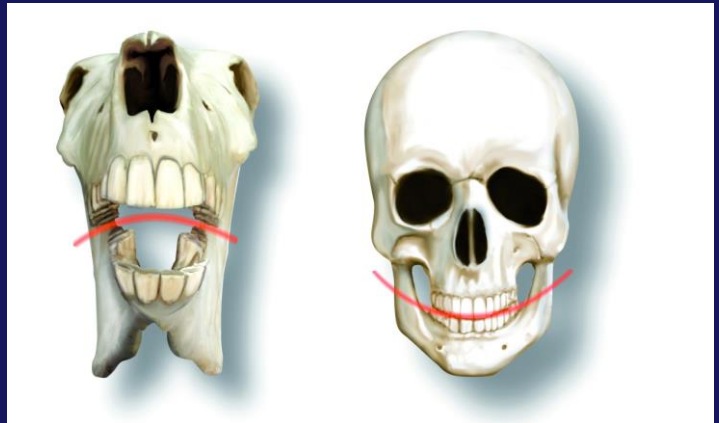
**Irregular dental arcade:  
Such as step mouth or wave**





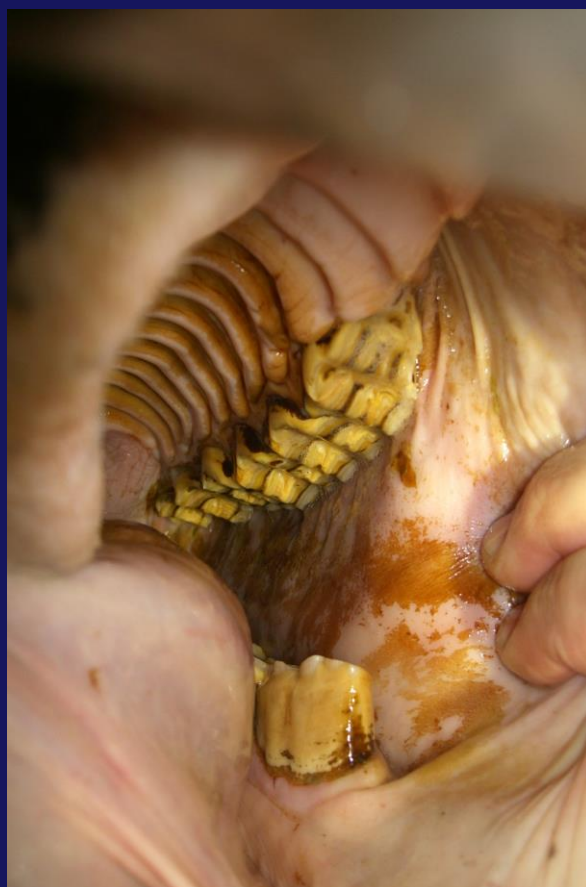
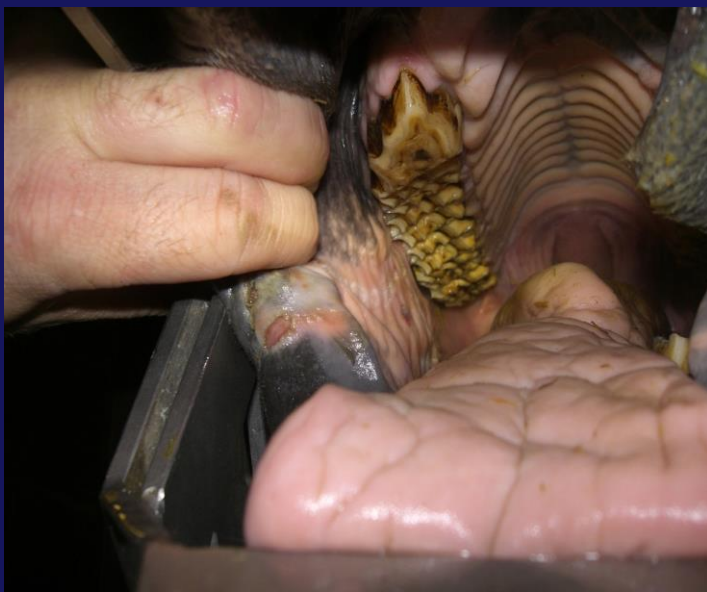
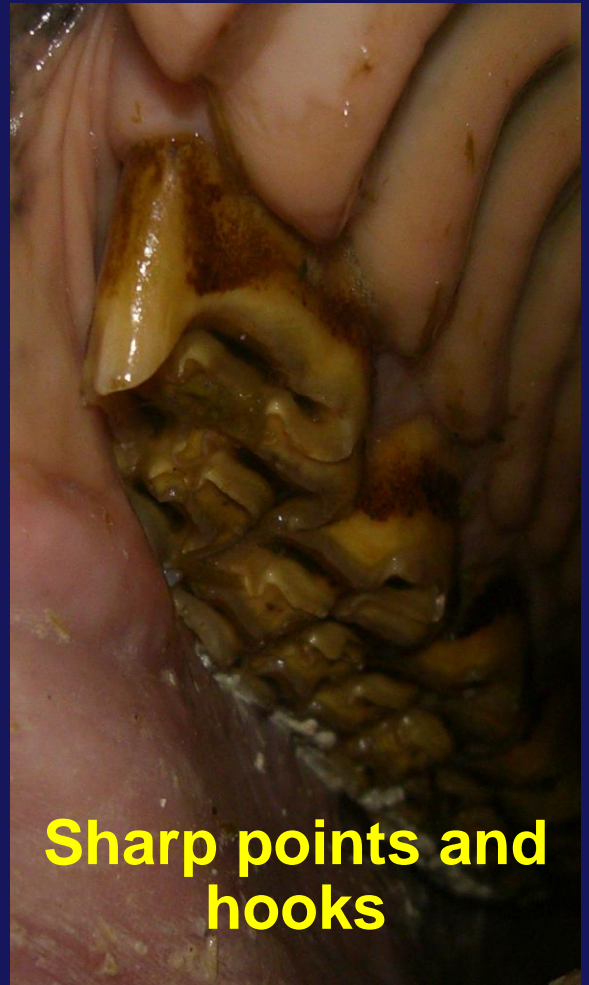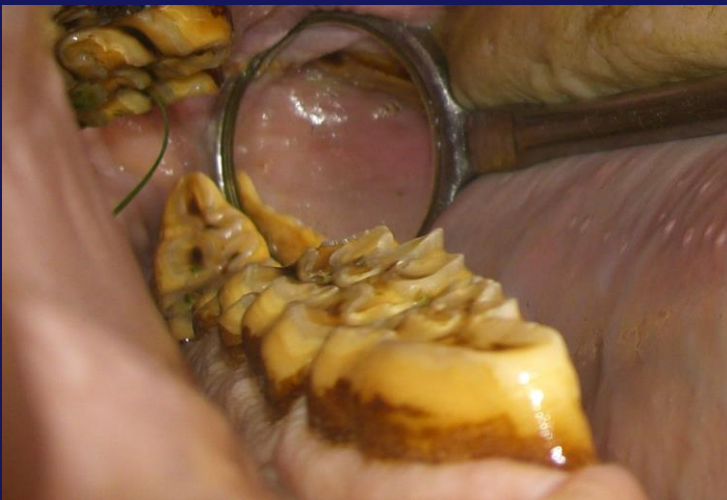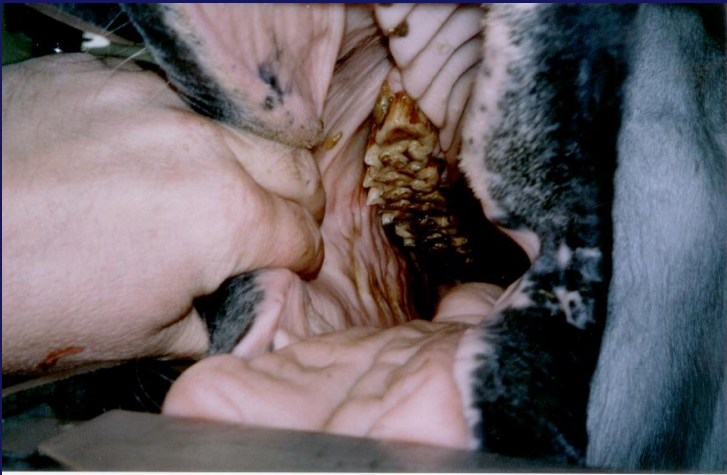Serious alteration of  
the cheek teeth table  
angle:  
Shear mouth



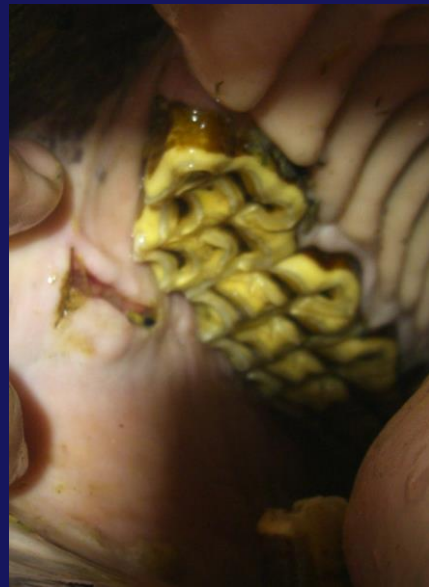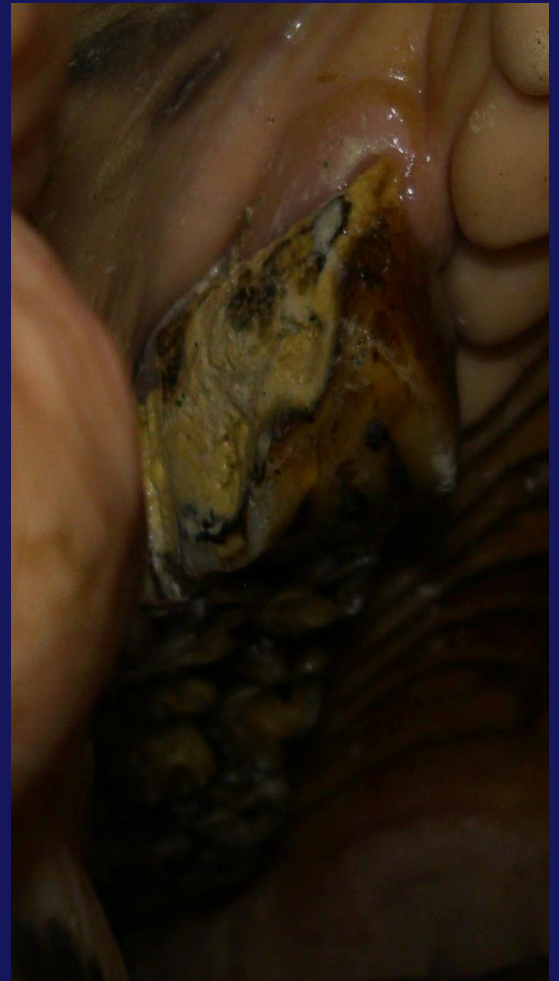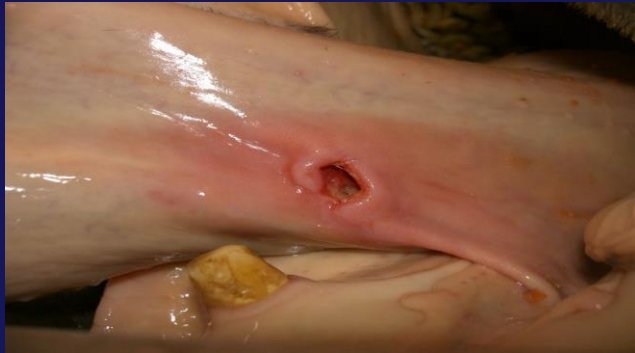*From: „Praxisleitfaden Zahn- und Kiefererkrankungen des Pferdes“ by T. Simon, I. Herold et H. Schlemper. Parey Editors, Stuttgart, 2009*

## Polyodontia and excessive transverse ridges



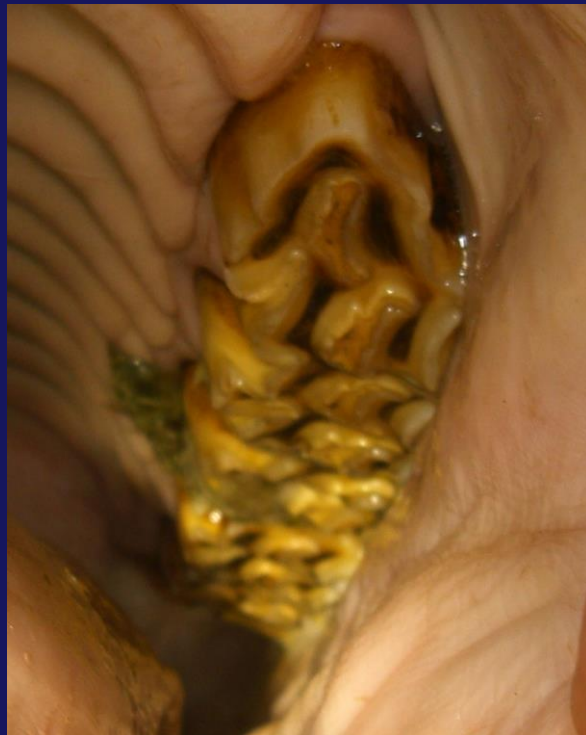

**Sharp points and hooks**



Surrounding  
tissues

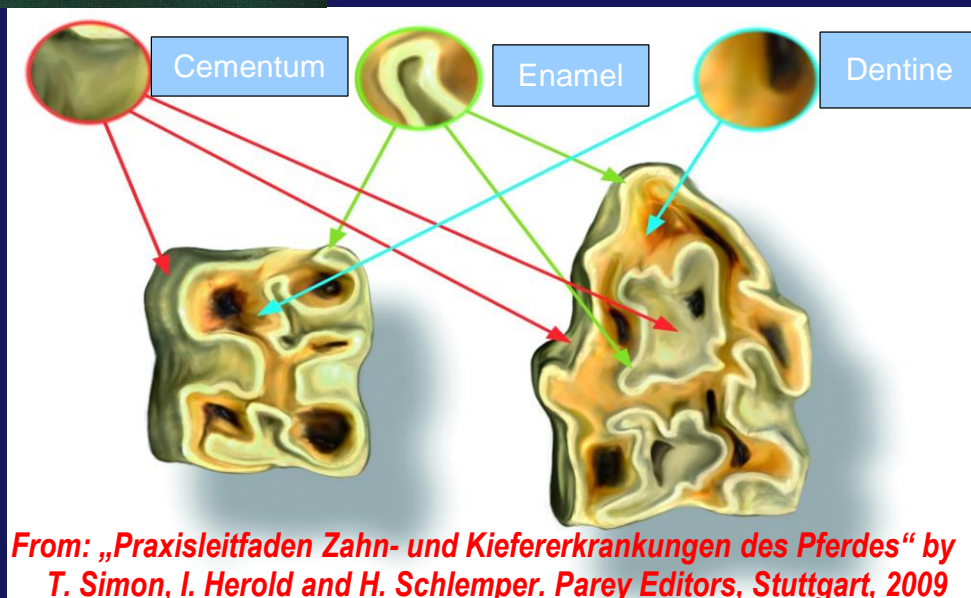

## Diastemata and periodontal disease



# Inspection of the molar tables, the sides of the clinical crown and the gingiva

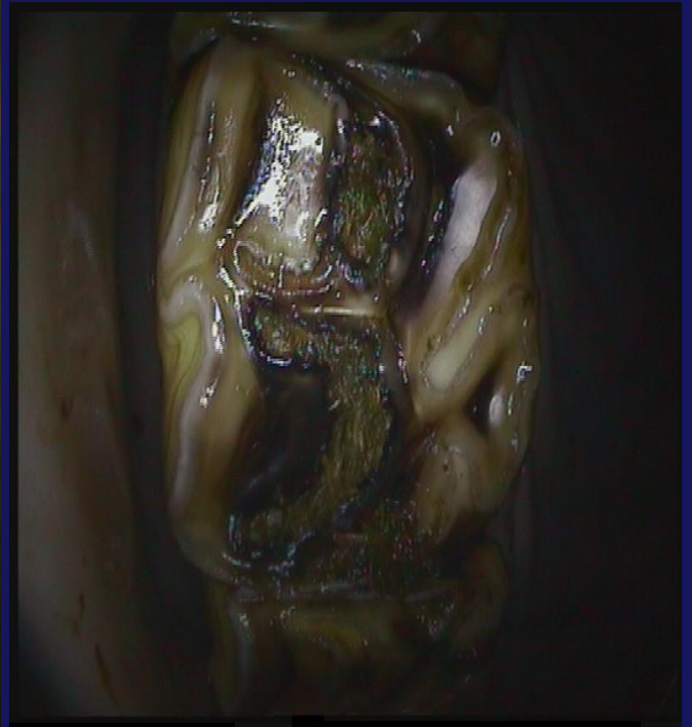
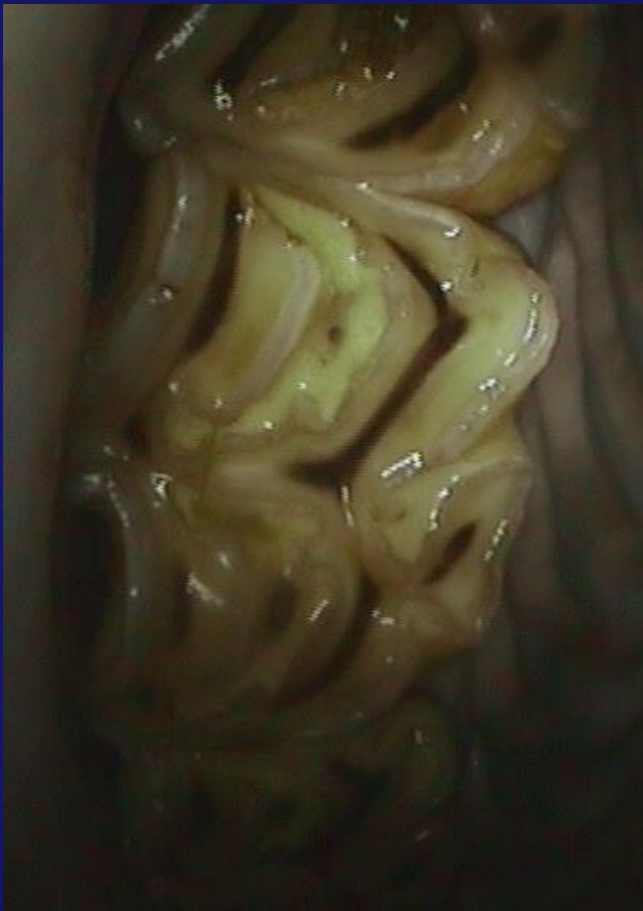

## Premolar and molar chewing tables



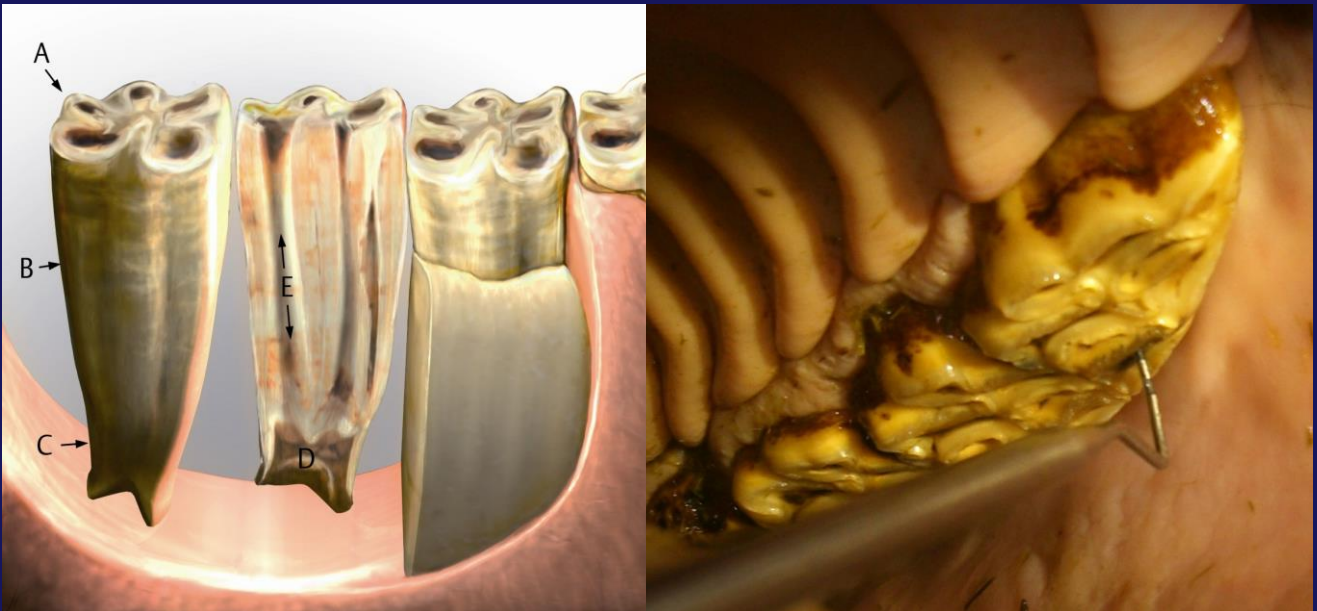
*From: „Praxisleitfaden Zahn- und Kiefererkrankungen des Pferdes“ by T. Simon, I. Herold and H. Schlemper. Parey Editors, Stuttgart, 2009*

## Infundibular decay





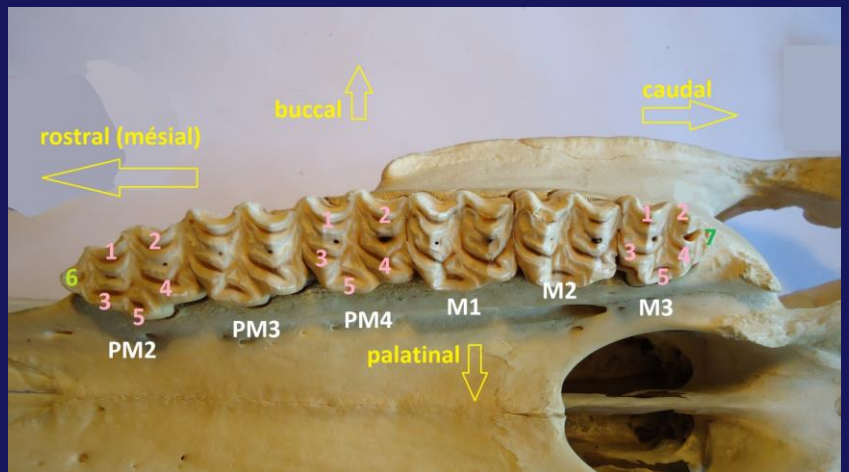
## Pulp positions



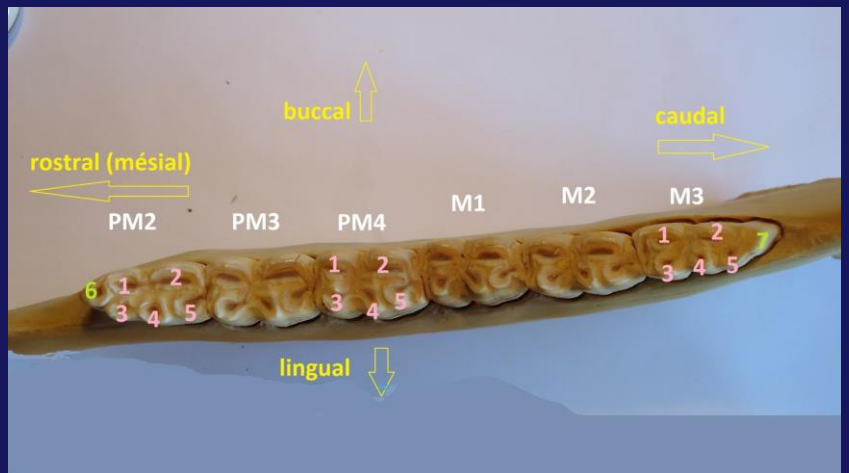
De: „Praxisleitfaden Zahn- und Kiefererkrankungen  
des Pferdes“ by T. Simon, I. Herold and H.  
Schlemper. Parey Editors. Stuttgart, 2009

# Pulp positions: Nomenclature

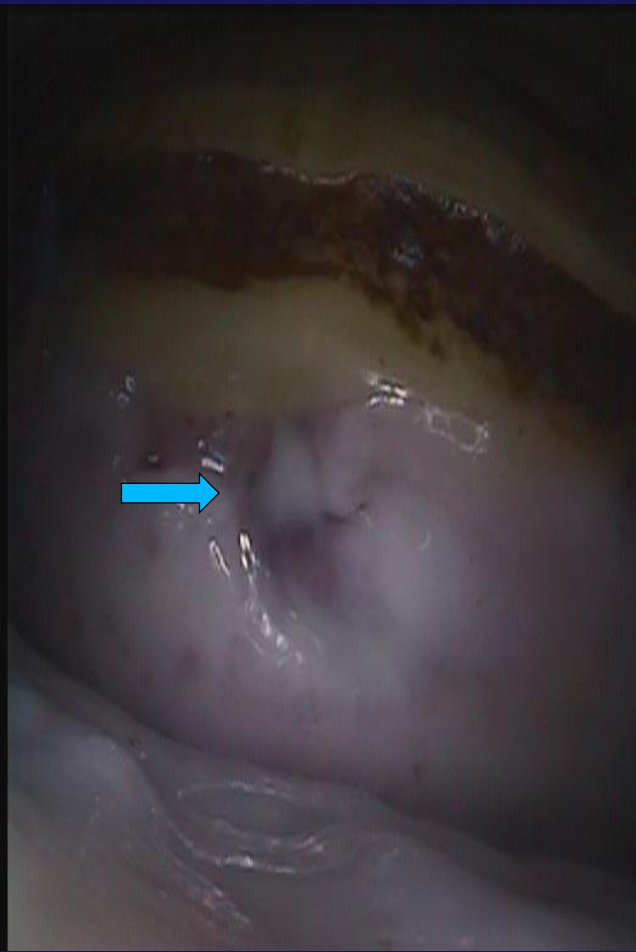Left maxillary arcade



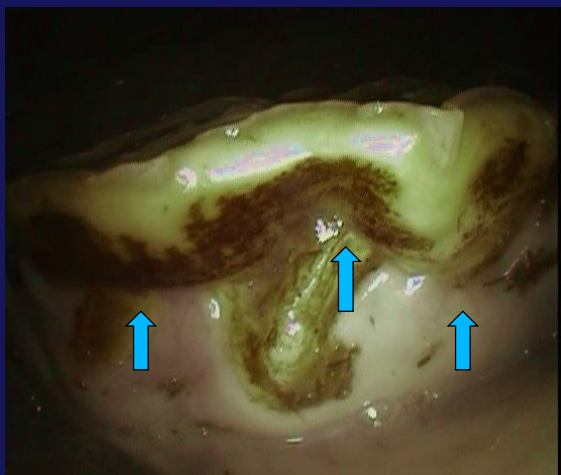
Right mandibular  
arcade



Inspection of lateral aspects of the clinical crown and the surrounding gingiva



## Lateral aspect of cheek teeth: caps

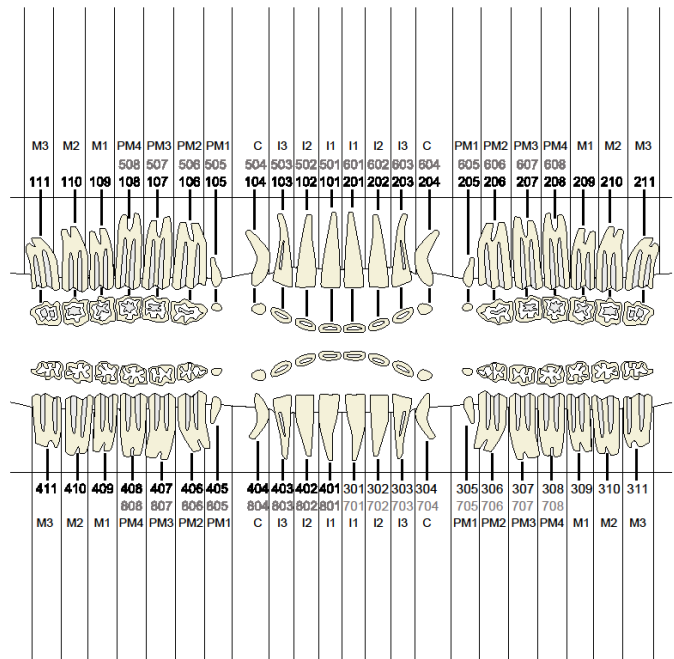


# Treatment plan and records

- Anamnesis
- Inspection of the patient
- Inspection of the patients head
- Palpation
- Inspection and palpation of the incisors and surrounding tissues
- First inspection of the mouth (undated)
- Evaluation of general health
- Sedation
- Place mouth gag
- Rinse the mouth
- Inspection with dental mirror and/or endoscope
- Inspection with dental probes
- Establish treatment plan

## BEFUNDBOGEN

Besitzer \_\_\_\_\_ Datum \_\_\_\_\_ Anamnese / Befunde / Anweisungen / Nachbehandlung \_\_\_\_\_  
 Patientenname \_\_\_\_\_  
 Signalement \_\_\_\_\_  
 Sedation \_\_\_\_\_



Okklusion      Endodontie      Parodontium      Schneide-/Hengst-Wolfszähne  
 re      li      re      li      re      li      re      li

Four cross-shaped diagrams are provided for recording clinical findings. Each diagram has 're' on the left and 'li' on the right, corresponding to the labels above.

**Lets go to  
work!**

