

A Review of Conditions of the Equine Temporomandibular Joint

H. David Moll, DVM, MS, Diplomate ACVS; and
Kimberly A. May, DVM, MS, Diplomate ACVS

The equine temporomandibular joint is poorly understood, and minimal documentation exists in the veterinary literature. Conditions relating to the temporomandibular joint may include traumatic injuries, infection, head shaking, biting problems, and quidding. Intra-articular anesthesia is the best method of confirming joint involvement. Authors' address: Department of Veterinary Clinical Sciences, College of Veterinary Medicine, Oklahoma State University, Stillwater, OK 74078. (Moll and Surgi-Care Center for Horses, Brandon, FL 33511 (May). © 2002 AAEP.

1. Introduction

The temporomandibular joint (TMJ) is a complex diarthrodial joint consisting of dorsal and ventral compartments divided by a fibrocartilaginous intra-articular disc. The two compartments do not communicate in normal animals. Communication only occurs if there is damage to the disc or its capsular attachments. The ventral compartment is substantially smaller than the dorsal. Minimal descriptive information of normal equine TMJ anatomy is found in the veterinary literature. There are only brief descriptions of the osseous structures and the muscles of mastication (Fig. 1).^{1,2} The TMJ of herbivores differs from that of carnivores. The joint surface of the herbivore is more incongruent, allowing more mediolateral freedom of motion.¹⁰ This lateral motion is vital in herbivores for molar occlusion in grinding forage. The parotid salivary gland is in close proximity and may overlie the caudal portion of the TMJ. In contrast to other joints, the articular surfaces of the TMJ are covered with fibrocartilage instead of hyaline cartilage.⁴

TMJ dysfunction is a recognized and well-described clinical entity in humans. Clinical manifestations in humans include headache, neck ache, tinnitus, earache, dizziness, and visual disturbances in addition to the more commonly observed signs of localized pain, abnormal sounds produced during translation of the joint, and restricted joint motion. Despite the recognition of TMJ dysfunction in humans, the exact etiology is often unknown. Spasm of the extrinsic musculature, intra-articular pathology such as displacement of the intra-articular disc, and dental abnormalities have been found to contribute to TMJ dysfunction.⁴⁻⁶

2. Conditions of the TMJ

TMJ conditions in the horse have been largely unrecognized. TMJ conditions in horses may be overlooked because of the nonspecific nature of the clinical signs. Clinical signs of diagnosed TMJ conditions in horses include dysphagia due to masticatory problems,⁷⁻⁸ malocclusion,⁹⁻¹¹ localized pain^{13,14} decreased range of motion of the mandible,^{7,9,11} and fistulous tract formation.⁷ Veterinary

NOTES

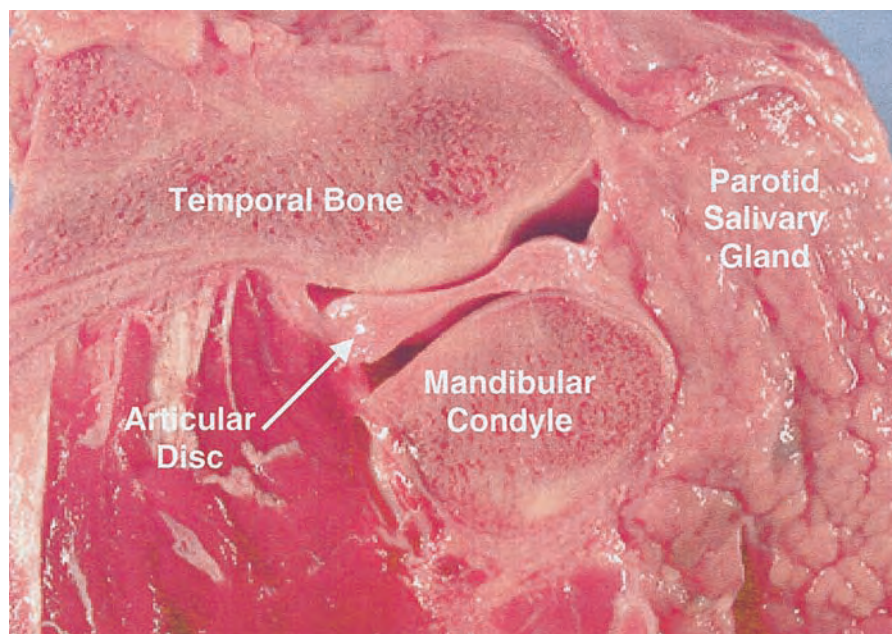


Fig. 1. Central sagittal section of the equine temporomandibular joint.

clinicians have reported abatement of clinical signs of common behavioral problems including head-shaking, quidding, and apparent masticatory problems after intra-articular anesthesia of the TMJ, suggesting that these problems were related to TMJ pain.

Clinical signs associated with the TMJ in horses have generally been the result of traumatic injuries. Conditions such as dysplasia, masticatory myositis, craniomandibular osteopathy, and hypertrophic osteodystrophy¹⁶ have been reported in small animals but not in the horse. Luxation of the equine TMJ results in impaired prehension and inability to appose the upper and lower incisors.⁹⁻¹⁰ Infection of the TMJ can occur secondary to penetrating wounds and osteomyelitis.^{7,14} Correction of abnormal incisor growth and wear in equine patients resolved clinical signs of TMJ pain in the horse. It was concluded that proper dentistry might be responsible for reducing TMJ inflammation.¹⁵

3. Diagnostic Techniques

With most joint injuries, an excess of synovial fluid accumulates within the joint. Unless there is serious joint damage, such as intra-articular fragmentation, the effusion may not be grossly visible. Careful palpation and comparison to the contralateral joint may give an indication of excessive effusion. As with other joints, synovial fluid analysis may provide information that helps in the diagnosis and therapy of the TMJ. This is particularly true in diagnosis of septic arthritis. In addition to analysis of the joint fluid, a positive response to intra-articular anesthesia is indicative of TMJ pain.

The TMJ is located by following a horizontal line from the lateral canthus of the eye directed caudad. Confirmation is obtained by manipulation of the mandible. This results in palpable excursion of the mandibular condyle relative to the articular eminence. A depression (caudal synovial pouch) is palpable just dorsal and caudal to the temporal and mandibular prominences.¹⁷ A 20-gauge 1.5-cm needle is used. If diagnostic anesthesia is performed, 5–10 ml of local anesthetic is sufficient. The needle is directed rostrally and ventrally, at an angle of $\sim 40^\circ$ to the transverse plane and 45° to the skin surface.¹⁷ Alleviation of symptoms indicates that the TMJ is involved. One must then assess whether it is primarily a TMJ problem, or if the synovitis is secondary to other pathology such as dental disease.

Radiographic imaging capabilities of the equine TMJ are limited by the complexity of the equine skull, difficulties in positioning for multiple views, and superimposition of osseous structures.^{13-14,18-19} The lateral view, as well as the dorsal-ventral view is difficult to interpret due to superimposition. Oblique projections provide the best information, but are still restricted and may be difficult to interpret.^{14,19} Radiographs allow confirmation of TMJ luxation, and may facilitate detection of bone lysis or proliferation in cases of infection or degenerative changes.^{1,6,13}

Ultrasonographic anatomy of the equine TMJ allows noninvasive evaluation of the lateral joint capsule, articular disc, and joint surfaces. However, only the lateral aspect of the joint can be visualized, and the pterygoid ligaments cannot be differentiated

SURGERY

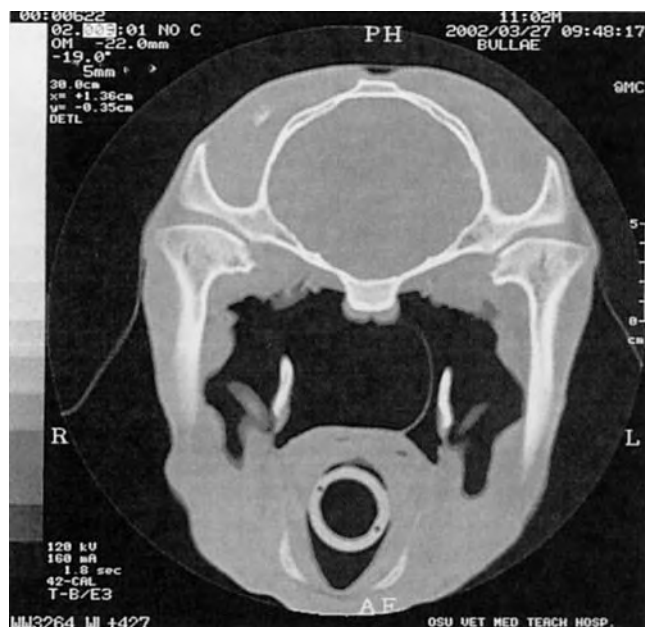

Fig. 2. CT scan of equine head. Sagittal section taken at the temporomandibular joint.

from the joint capsule.¹⁹ Ultrasonography of one horse confirmed a narrowed joint space with the absence of the articular disc and degenerative changes caused by osteomyelitis and subsequent bone necrosis.¹⁴

Nuclear scintigraphic imaging is a highly sensitive method of detecting abnormalities. Scintigraphy may localize a disease process to the TMJ area, but determining a diagnosis is limited by lack of specificity. Additional imaging, such as radiography or computed tomography, is usually necessary.^{2,14}

Computed tomographic (CT) imaging provides superior visualization of the TMJ (Fig. 2). Advantages to CT imaging include the avoidance of structural superimposition and the availability of objective measurement and three-dimensional reconstruction to determine anatomic relationships between structures.¹³ The disadvantages include added expense, need for general anesthesia, and necessary specialized facilities and instrumentation. CT imaging has been reported in the diagnosis and treatment of an avulsion fracture of the TMJ and has facilitated evaluation of the TMJ and associated structures in two horses with infectious TMJ.¹³

Magnetic resonance imaging (MRI) yields diagnostic images based on magnetic properties of tissue. The multiplanar capacity of MRI to acquire images in any desired slice plane without repositioning the patient is an advantage of MRI over CT. MRI excels in the evaluation of soft tissues as a result of the contrast that can be achieved between tissues.²⁰ In this aspect MRI may be superior to CT in imaging the articular disc and ligaments of

the TMJ; however, CT still offers the best image resolution of osseous lesions. The disadvantages of MRI are the same as those of CT.

In human patients, arthroscopic surgery has become a mainstay of diagnosis and treatment of TMJ conditions. The procedure offers a minimally invasive method of assessing the integrity of the articular surfaces and articular disc, and is associated with decreased complications and morbidity when compared to arthrotomy.⁴ Recently, the surgical approach and arthroscopic anatomy of the normal equine TMJ has been described.¹⁷ A 20-gauge, 1.5-inch needle is inserted into the caudal aspect of the dorsal compartment as described previously. The TMJ is distended with 8–12 ml of sterile lactated Ringer's solution to facilitate arthroscopic insertion. The arthroscopic approach is made over the most prominent part of the out pouching at the caudodorsal aspect of the synovial pouch. Arthroscopic evaluation could improve assessment of the TMJ in reported conditions such as luxation,^{1,6} penetrating trauma,^{2,19} and arthropathies.¹³ In the case of luxations, arthroscopic evaluation of the disc and articular joint surfaces may allow more accurate determination of prognosis. Certainly, early aggressive evaluation, debridement, and joint lavage may improve therapeutic success in cases of TMJ sepsis. When clinical signs of TMJ pain can be alleviated by intra-articular anesthesia, diagnostic arthroscopy may be indicated. There are limitations to arthroscopic evaluation of the TMJ. There is minimal visualization of the medial articular surfaces and reduced ability to observe the central portions of the articular disc and articular fossa.¹⁷

4. Discussion

The TMJ in most species is poorly understood. Even in humans where the joint has been studied the most extensively, the etiology of TMJ pain is unknown in many cases. It is likely that TMJ conditions in the horse may be more prevalent than currently realized. Pain caused by synovitis may be secondary to many of the dental malocclusions encountered during routine dentistry procedures.

Treatment of conditions of the TMJ should be similar to conditions of other joints. Infectious arthritis has been successfully treated with a combination of systemic antimicrobials, intra-articular antimicrobials, and joint lavage.^{7,14} Mandibular condylectomy resolved closed lock ankylosis of the TMJ in one horse. The procedure resulted in masticatory problems and prolonged difficulty in eating hay.⁷ Results with other joints should tell us that intra-articular hyaluronan or corticosteroids may be useful in treating TMJ synovitis, and whether it is a primary problem or initiated secondary to dental abnormalities. However, the efficacy of these medications in a joint with fibrocartilaginous surfaces may be different from that observed in joints with hyaline cartilage. Arthroscopic exploration of TMJ conditions unresponsive to conventional therapy

SURGERY

may give us further insight into previously unreported conditions in the horse that are not apparent with other imaging techniques. These could include lesions of the articular surface, articular disc, or synovial adhesions.

References

1. Getty R, ed. *Sisson and Grossman's the anatomy of the domestic animals*. 5th ed. Philadelphia: W.B. Saunders, 1975;80–83,335–6,655.
2. Nickel R, Schummer A, Seiferle E, ed. *The anatomy of the domestic animals, vol. 1. The locomotor system of the domestic mammals*. New York: Springer-Verlag, 1979;172–3,256–9,261–3.
3. Noble HW. Comparative functional anatomy of temporomandibular joint. *Oral Sci Rev* 1973;2:3–28.
4. Bush FM, Dolwick MF. *The temporomandibular joint and related orofacial disorders*. Philadelphia: J.B. Lippincott, 1995;3–35,51,87–130, 236–292.
5. Trumpy IG, Lyberg T. Surgical treatment of internal derangement of the temporomandibular joint: long-term evaluation of three techniques. *J Oral Maxillofac Surg* 1994;53:440–446.
6. Vallerand AH, Russin MM, Vallerand WP. Taking the bite out of TMJ syndrome. *Am J Nurs* 1999;688–690.
7. Patterson LJ, Shappell KK, Hurtig MB. Mandibular condylectomy in a horse. *J Am Vet Med Assoc* 1989;195:101–102.
8. McCain JP, de la Rúa H, LeBlanc WG. Puncture technique and portals of entry for diagnostic and operative arthroscopy of the temporomandibular joint. *Arthrosc J Arthroscopic Related Surg* 1991;7:221–232.
9. Hardy J, Shiroma JT. What is your diagnosis? (TMJ luxation). *J Am Vet Med Assoc* 1991;198:1663–1664.
10. Hurtig MB, Barber SM, Farrow CS. TMJ luxation in a horse. *J Am Vet Med Assoc* 1984;185:78–80.
11. Lantz GC. Surgical correction of unusual temporomandibular conditions. *Compend Cont Educ Pract Vet* 1991;13:1570–1576.
12. Barber SM, Doige CE, Humphreys SG. Mandibular condylectomy: technique and results in normal horses. *Vet Surg* 1985;14:79–86.
13. Tietje S, Becker M, Bockenhoff G. Computed tomographic evaluation of head disease in the horse: 15 cases. *Equine Vet J* 1996;28:98–105.
14. Weller R, Cauvin ER, Bowen IM, et al. Comparison of radiography, scintigraphy and ultrasonography in the diagnosis of a case of temporomandibular arthropathy in a horse. *Vet Rec* 1999;144:377–379.
15. May KJ. Incisor problems that may result in inflammation of the temporomandibular joint, in *Proceedings*. 15th Meeting Equine Welfare Sports Med 1996;716.
16. Robins G. Disease of the temporomandibular joint and associated structures. *Aust Vet Pract* 1982;12:102–104.
17. May KA, Moll HD, Howard RD, et al. Arthroscopic anatomy of the equine temporomandibular joint. *Vet Surg* 2001;30:564–571.
18. Metcalf MR, Tate LP, Sellet LP. Clinical use of ^{99m}Tc-MDP scintigraphy in the equine mandible and maxilla. *Vet Radio* 1989;30:80–87.
19. Weller R, Taylor S, Maier J, et al. Ultrasonographic anatomy of the equine temporomandibular joint. *Equine Vet J* 1999;31:529–532.
20. Tucker RL, Farrell E. Computed tomography and magnetic resonance imaging of the equine head. *Vet Clin North Am Equine Pract* 2001;17:131–144.