

A New Look at Dental Radiology

Jack Easley, DVM, MS, Diplomate ABVP

High-quality, diagnostic equine dental radiographs can be taken under field conditions by using portable X-ray equipment. Utilizing a stand to support the head of the sedated horse and X-ray cassette, repeatable motionless films can be taken. Holding the horse's mouth open with a PVC pipe gag brings the upper and lower cheek teeth out of occlusion and decreases superimposition of the arcades. Author's address: P.O. Box 1075, Shelbyville, KY 40066. © 2002 AAEP.

1. Introduction

Equine Practitioners must change their way of observing dental problems. The *etiology* of dental disease must be foremost in the process of evaluation. Proper diagnosis and therapy planning cannot be undertaken until the etiologies of disease are identified. "We look but we don't see".

Thomas Kuhn in his paper, "The Structure of Scientific Revolutions," states that every breakthrough in the field of science is first a break with tradition of old ways of thinking or old paradigms.¹ It is time for us as veterinary professionals to break with tradition and "see" dental problems in a new light.

For years, equine surgeons have found equine skull radiology to be a valuable tool in the diagnosis and management of dental disease. Radiology has been useful in evaluating the embedded crown and root or apical portions of the horse's tooth, surrounding bones, and sinuses.²⁻⁴ Radiology has been of limited value in the assessments of lesions involving the gingival margins or evaluation of the exposed tooth crown.⁵

The excellent contrast between air, bone, soft tissue, and tooth substance make the head an ideal area for radiographic evaluation. Conventional or standard radiographic projections adequately image

the reserve crown apices, lamina dura denta, alveolar space, and alveolar bones, as well as changes in the associated maxillary, mandible, and sino-nasal structures. With these conventional closed-mouth radiographic projections, the erupted crown is obscured by superimposition of the crowns of the opposite dental arcades.

Several factors may limit the practitioner from acquiring good-quality films (i.e., size of the horse, types of intensifying screens and films, and exposure capabilities of the portable X-ray machine). Some limitations can be overcome by reducing motion in the horse's head and appropriate positioning of the X-ray cassette and X-ray machine while taking the radiograph. The differences in tissue density and the increasing width of the horse's head from rostral to caudal may require more than one radiographic exposure of an anatomical area to highlight the tissues to be evaluated.

In order to generate the required image, knowledge of skull anatomy and topographic landmarks is necessary to insure correct positioning of the X-ray unit, cassettes, and horse's head. The head is anatomically complex, necessitating the use of large cassettes (34 cm × 43 cm) 14" × 17" in order to

NOTES

maintain spatial relationships when evaluating the radiograph. Coning down on the radiograph will allow better contrast and detail over a smaller area of greater concern. It is helpful to use both right and left projections in order to take advantage of image sharpness and magnification in the location of interest. Because of age-related changes in the hypodont teeth of the horse, it is beneficial at times to take lesion-oriented oblique views of the affected area and the opposite (normal) side of the skull to have a comparison film to evaluate.

With the recent introduction of open-mouth oblique radiographic views, a more accurate diagnosis of lesions affecting the clinical crowns of the cheek teeth, can be made.^a By using the following techniques, the equine practitioner in the field can utilize diagnostic open-mouth radiographs of the skull with portable X-ray equipment.

2. Materials and Methods

In this study, a high-frequency portable X-ray unit capable of generating 80 KVp and 15 MA was utilized. Also used were 34–43 cm medium or regular speed rare earth cassettes with fast-speed film without a grid. Films were taken at a focal film distance of 80–100 cm. A table or headstand with a flat surface (~100 cm off the ground) was used to support the sedated horse's head. Smaller cassettes were used for lesion-oriented oblique films. Wooden or foam blocks were used to position the head and X-ray cassettes. These blocks were also used to support small cassettes and elevate the cassettes to the height of the cheek teeth arcades. A blindfold or towel placed over the horse's eyes aided in restraint and helped avoid motion artifacts. Three different 10-cm sections of PVC pipes were used as mouth gags. A 7.5-cm-diameter section of pipe was used on smaller horses or ponies. This diameter equates to two clicks on the standard McPherson mouth speculum. Sections of 9-cm diameter and 11.5-cm diameter PVC pipe were used to wedge the mouth open in larger horses. Two 3-m long pieces of 0.5-cm-diameter cotton or nylon rope were used to steady the horse's head and/or put traction on the mandible. A cassette holder and suitable radiation protection equipment consisting of gloves, apron, and thyroid guards was made available to all personnel in the immediate area.

Heavy sedation of the horse is necessary both to safely obtain skull radiographs and to facilitate separation of the maxillae and hemi-mandibles. A combination of xylazine hydrochloride, 0.3–0.6 mg/Kg or detomidine hydrochloride, 10–20 mcg/Kg with butorphanol tartrate 10 mcg/Kg provides 20–30 min of heavy sedation. This allows time for a comfortable and detailed oral examination and relaxed, motionless radiographs with the horse resting its muzzle on the table or support stand.

Standing Open-Mouth Lateral Radiograph

Position the sedated horse's head on a stand with a pipe gag between the incisor teeth. The tongue should protrude through a hole in the PVC pipe in a normal, relaxed position. The head should rest on the pipe clutched between the incisor teeth. Place a 34 cm × 43 cm X-ray cassette against the face on the affected side. The cassette should rest comfortably on the same stand as the horse's head and should be centered in the area of the facial crest. Position the X-ray tube 100 cm from the cassette with the center of the beam just below the rostral edge of the facial crest. The X-ray tube should be perpendicular to the horse's head in the vertical and horizontal planes. This minimizes distortion and maximizes image standardization.

Open-Mouth Oblique Radiographs

For oblique films, the horse's head is positioned in the same manner as for lateral projections. The tube head is moved to the optimal angle of incidence of the X-ray beam for the projection required. For visualization of maxillary cheek teeth, the standard 30° dorsolateral lateral oblique view is taken. For the mandibular cheek teeth, a 35–45° ventrolateral lateral oblique view is taken. To image the clinical crowns of the maxillary and mandibular cheek teeth, 10–15° ventrolateral lateral and dorsolateral lateral oblique views taken from the opposite side prove optimal.^a For lesion-oriented oblique films the X-ray beam is directed at a 45° angle to visualize the entire tooth from apex to crown (Fig. 1).

Dorsoventral (DV) or Ventrodorsal Radiographs

To visualize the sinuses and nasal septum, a centered DV radiograph with the mouth closed is recommended. To better visualize dental arcade pathology, an off-centered or oblique open-mouth DV projection works well. The mouth should be wedged open with a PVC pipe gag between the incisor teeth. For viewing the upper or maxillary arcade, a ventrodorsal projection with the cassette resting on the dorsal aspect of the skull and the tube head near the floor provides the clearest image. The lower jaws can be retracted to the right or left to reduce superimposition of the upper and lower cheek teeth. This is done by placing two nylon cords around the lower and upper jaws, placing traction in opposite directions, thus displacing the arcades as much as 6–8 cm. Lesion-oriented obliques can be used to outline the peripheral margins as well as the enamel folds and infundibulum of the cheek teeth. For lesion-oriented films, smaller cassettes with slower more detailed film/screen combinations and shorter focal film distance can be used. For visualizing the lower cheek teeth, a DV view is best. The lower jaw is narrow and must be obliqued slightly to the medial or axial plane with the lower jaw retracted axially.

DENTISTRY

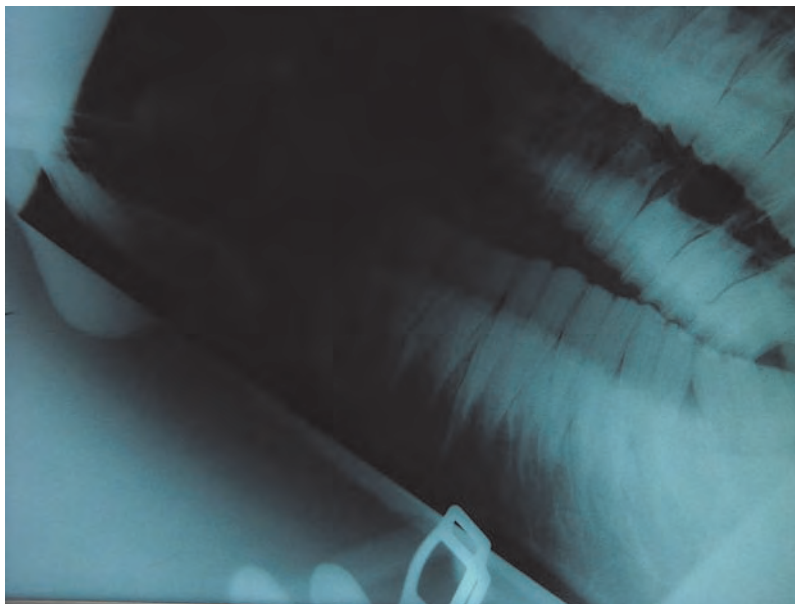


Fig. 1. Open-mouth 45° ventrolateral lateral oblique radiograph showing the cheek teeth arcades from apex to crown. This 12-yr-old, Warmblood mare had her mouth wedged open with a piece of 11.5-cm-diameter PVC pipe.

3. Results

The use of open-mouth radiographs has evolved over the past 5 yr. The utilization of a head stand to reduce motion and the mouth gag to do away with superimposition of the cheek teeth arcades have become a standard practice. Equine patients selected for dental radiology have been presented with a wide range of complaints and clinical signs. Indications for open-mouth radiology are based on a history or owner's complaint or findings from a physical or oral examination.

Dental radiographs have been used to aid in the diagnosis of 92 cases over the past 3 yr. This constitutes about 2.78% of the cases presented for oral examination and dental treatment. Seven cases are presented that represent examples of radiology used to augment the physical examination.

Case #1

Open-mouth 15° dorsolateral lateral oblique radiograph of a 26-yr-old Arabian mare. This obese mare had a history of chronic laminitis and Cushing's syndrome. She quitted grass and hay but ate pellets and processed complete feed without difficulty. Oral examination revealed severe dental crown wear abnormalities and gingival hyperplasia. Diastema were present between the cheek teeth with severe pocketing of feed between the lower cheek teeth. Radiographs helped establish a baseline for therapy planning. The owners were able to better understand the mare's oral pathologies after reviewing the radiographs (Fig. 2).

Case #2

Open-mouth lateral radiograph of a 12-year-old Thoroughbred mare. She was presented for

chronic weight loss and dribbling grain. Oral examination revealed a tall lower left last cheek tooth. Feed material was packed in a periodontal pocket between the last two cheek teeth. Radiographs revealed an extra caudal lower molar (polydontia) with a tall crown. A diastema opening on the occlusal surface was present between 311 and the extra molar. The tall lower tooth crown was reduced. This alleviated the clinical signs. The owner was made aware of the periodontal pocket and educated regarding proper long-term care for this condition (Fig. 3).

Case #3

Open-mouth 30° dorsolateral lateral oblique radiograph of a 5-yr-old Tennessee Walking Horse mare. The mare was presented with a biting problem. Oral examination revealed what appeared to be a worn smooth 106 and a tall 406. Radiographs revealed a worn 506 cap with no permanent 406. Further oral evaluation demonstrated the 506 fragment to be loose and this was easily extracted. The tall lower tooth crown was reduced. This treatment relieved the biting problem (Fig. 4).

Case #4

Open-mouth 45° dorsolateral lateral oblique radiograph of an 8-yr-old Thoroughbred mare. The film was taken just after a standing oral extraction of 208 and maxillary sinus lavage. The post-operative film confirmed a clean dental socket without superimposition of the opposite dental arcades (Fig. 5).

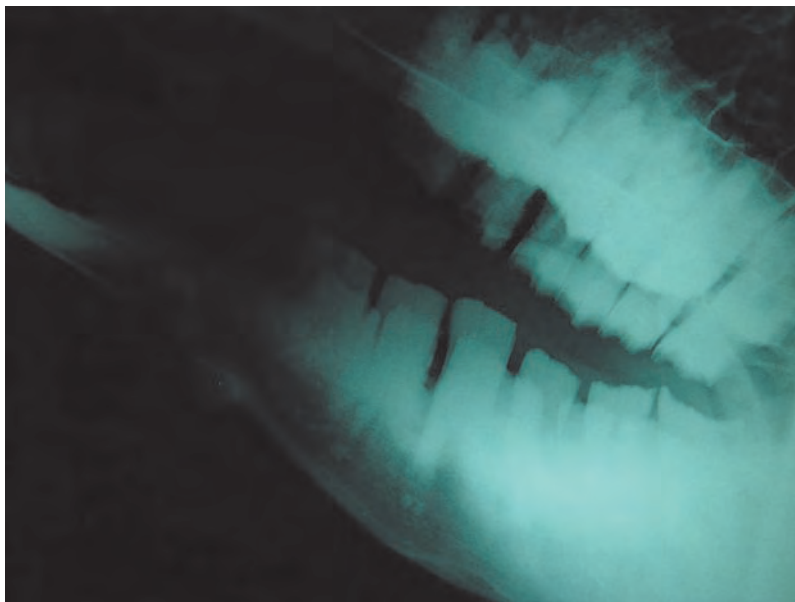

Fig. 2. Open-mouth 15° dorsolateral lateral oblique radiograph of a 26-yr-old mare detailed in Case #1.

Case #5

Open-mouth 30° dorsolateral lateral oblique radiograph of an aged Quarterhorse mare. She had been losing weight and quidding grass and hay. Additionally, the mare made a squeaking sound when chewing her grain and pellets. Radiographs revealed the extent of the wear abnormalities and the amount of tooth crown and root present. An informed treatment plan and prognosis was present to the owner based on the examination and radiographic findings (Fig. 6).

Case #6

Open-mouth 10° ventrolateral lateral oblique radiograph of a 17-yr-old Appaloosa mare. The mare had sustained an accident when the teeth were floated by an "equine dentist" 30 d before. Since the dentistry, the mare became extremely head shy. Physical examination revealed a firm enlargement on the ventral aspect of the mandible. Oral examination revealed a fractured crown on the left upper first molar (209). Radiographs confirmed the 209 dental crown fracture as

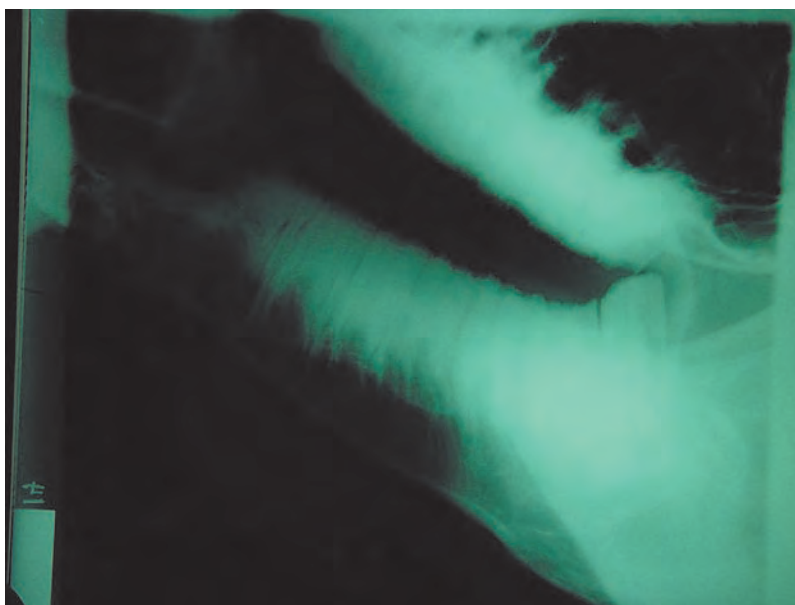


Fig. 3. Open-mouth lateral radiograph showing an extra lower last cheek tooth detailed in Case #2.

DENTISTRY

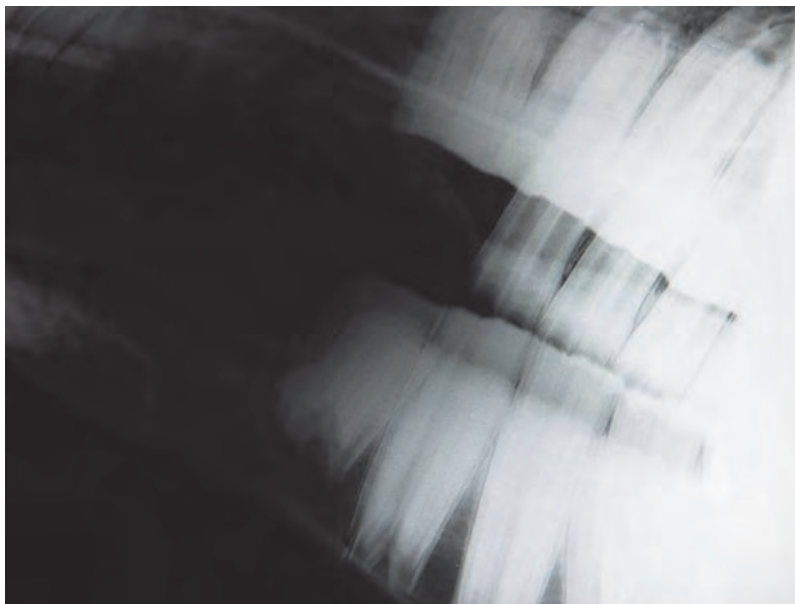


Fig. 4. Open-mouth 30° dorsolateral lateral oblique radiograph demonstrating a worn 506 deciduous tooth with no associated permanent tooth as detailed in Case #3.

well as an undisplaced healing mandibular fracture (Fig. 7).

Case #7

Open-mouth 10° DV lateral oblique radiograph of a 7-yr-old American Saddlebred gelding. During annual oral examination, an exaggerated transverse ridge was detected on 208 and a fractured crown on 308. Radiographs confirmed the fractured exposed crown of 308. The reserve crown and root of 308 was

deformed. This explained the etiology of the crown fracture (Fig. 8).

Case #8

Open-mouth 30° dorsolateral lateral oblique radiograph of a 5-yr-old miniature stallion. The horse was presented with a chronic ocular infection and a unilateral fetid nasal discharge. Oral examination revealed partially displaced upper premolar threes. A diastema was present between the last

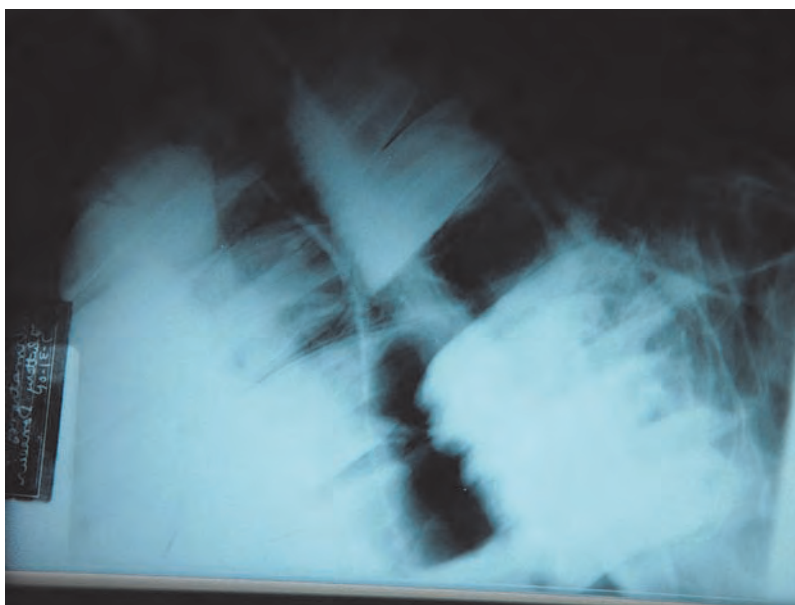


Fig. 5. Post-operative (oral dental extraction of 208) open-mouth 45° dorsolateral lateral oblique radiograph as detailed in Case #4.

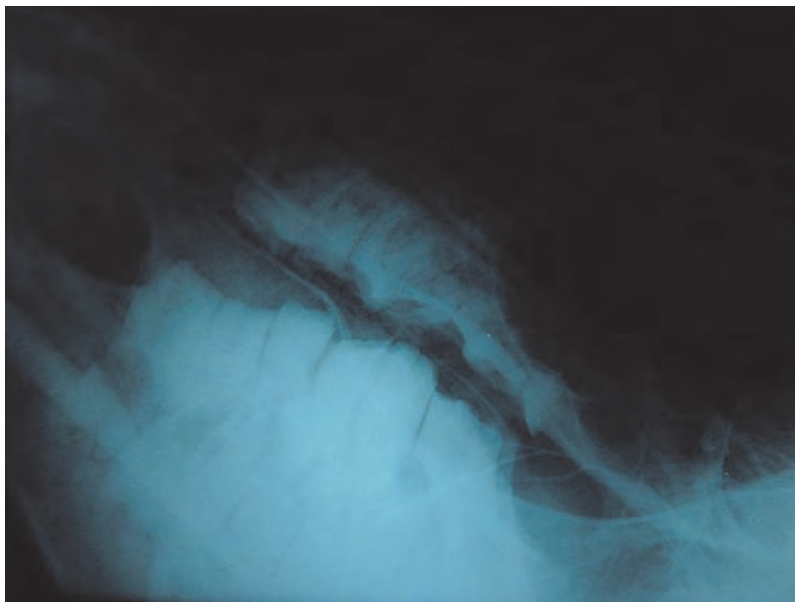


Fig. 6. Open-mouth 30° dorsolateral oblique radiograph of an aged, smooth-mouthed mare as detailed in Case #5.

two upper cheek teeth. Only five upper cheek teeth were present on each arcade. A normal set of six lower cheek teeth were present in each jaw. Radiograph revealed a valve diastema between the last two upper cheek teeth (Fig. 9).

Open-mouth DV radiograph with the mandible retracted away from the affected side confirmed oral findings. The second upper molar teeth appeared to be missing (oligodontia). The last upper molar appeared to be rotated with a deep buccal oral antral fistula into the maxillary sinus (Fig. 10).

4. Discussion

Many equine practitioners still fall under the cloud of ignorance expressed by Youatt in his text on the horse published almost 160 yr ago. "Of diseases of the teeth in horses, we know little." Youatt did state that equine teeth grow irregularly in length from not being in exact apposition to each other when the mouth is shut. He observed that elongations can penetrate the bars above and cause soreness, ulcerations, or interfere with grinding motions

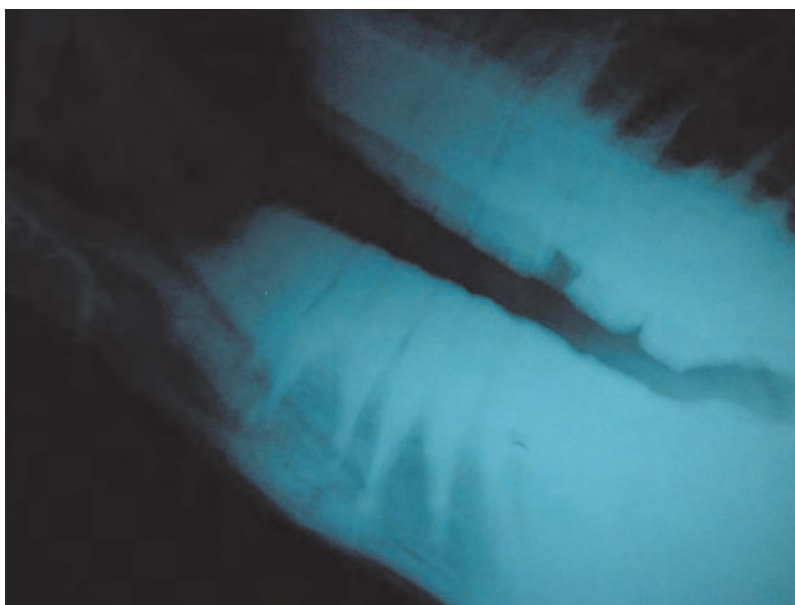


Fig. 7. Open-mouth 10° ventrolateral lateral oblique radiograph demonstrating a 209 crown fracture and an undisplaced healing mandibular fracture as detailed in Case #6.

DENTISTRY




Fig. 8. Open-mouth 10° DV oblique radiograph taken just after dental floating. A fracture 308 exposed crown and deformed reserve crown and apex is demonstrated and detailed in Case #7.

of the jaws. An animal with this problem can simply “pine away” without the cause being suspected. Once the teeth have become irregular, the horse is materially lessened in value. Even if the elongations are corrected, the projection will recur. Such a horse is, for all intents and purposes, unsound.⁶

Over a half century ago, Dollar stated that many dental abnormalities in the horse can exist for a long time and not cause any inconvenience. He went on to emphasize that once a dental condition progresses

to the point of causing a clinical problem, the prognosis is grave and treatment only palliative.⁷ It is known from several cadaver studies that the incidence of dental disease is as high as 80% in the skulls studied.⁸ In several more recent clinical studies, it has been determined that dental abnormalities can exist without the horse showing adverse clinical signs.^{9,10}

Since Dr. Uhlinger presented the results of her survey of selected dental abnormalities at the American Association of Equine Practitioners Meeting

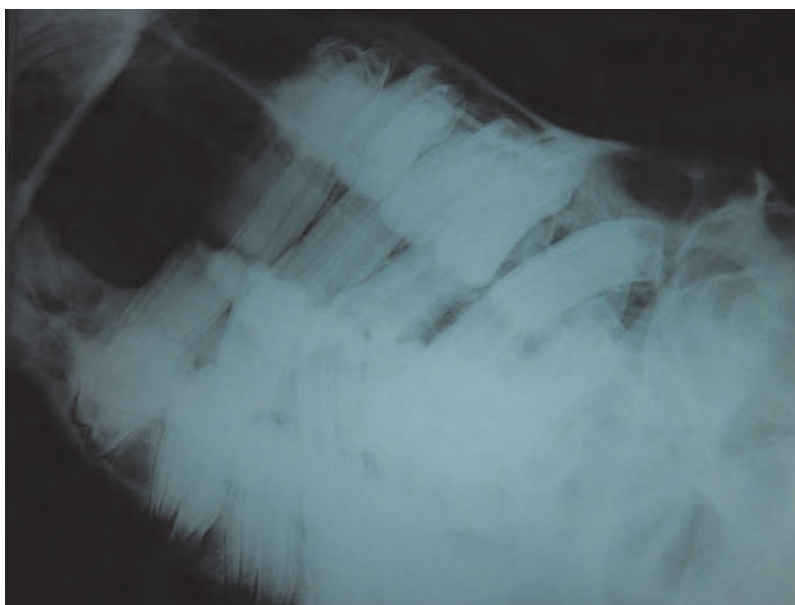


Fig. 9. Open-mouth 30° dorsolateral lateral oblique radiograph with oligodontia as detailed in Case #8.

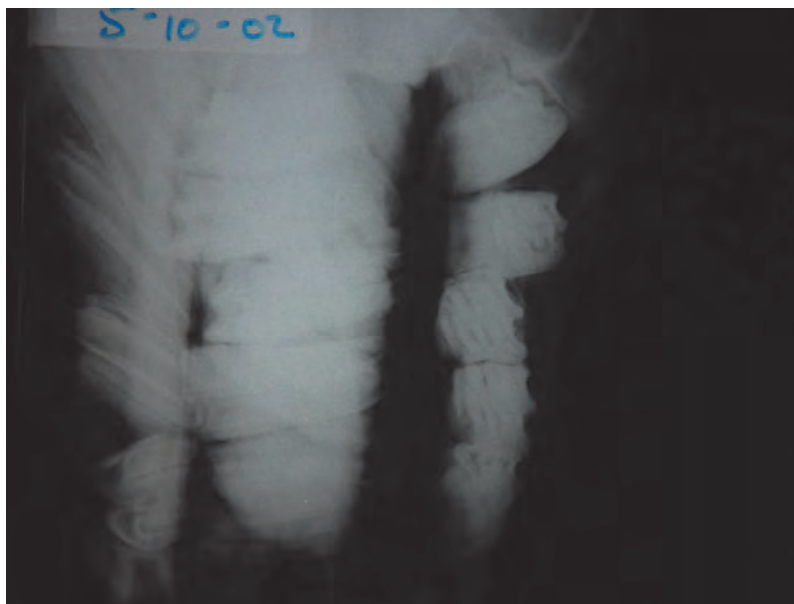


Fig. 10. Open-mouth, off-centered DV radiograph of the maxillary arcade demonstrating palatal displacement of 208, a missing 210, and a diastema between 209 and 211 as detailed in Case #8.

almost 15 yr ago, much progress has been made in equine dentistry.⁹ Equine surgeons have traditionally placed most emphasis in equine dentistry on disorders of the apices and reserved crowns. Only recently have detailed studies been published on diseases on the erupted or clinical crown.¹⁰

Today, many veterinarians perform a more complete dental examination. The use of sedation and a wide variety of full-mouth speculums and instruments such as metal basket retractors, dental picks, long-handled mirrors, and flexible endoscopes have become the norm. Intra-oral digital imaging has allowed veterinarians to capture still photographs or video of dental pathologies. Abnormalities can be visualized before and after treatment. Digital images can be shared with colleagues over the Web, making consultations and referrals more convenient and timely.

These diagnostic improvements have dealt with intra-oral findings. Many areas of the oral cavity cannot readily be clinically examined in the horse especially if the caudal cheek teeth are affected. Most of the horse's tooth is buried beneath the gum and guarded from visual examination and manipulation by the bones of the skull. Intra-oral films have been used to obtain radiographs of individual cheek teeth in the horse. The need for general anesthesia and relatively high exposures make this technique impractical in the field.² Recent advances in alternative imaging techniques for the equine head such as nuclear scintigraphy, computerized tomography, magnetic resonance imaging, and digital radiology aide in diagnosing and planning of therapy for many equine dental disease conditions. The expense

and sophistication of these modalities of diagnostic imaging techniques, limit their use in a field situation.¹¹⁻¹³

A technique that has been underutilized in the field has been radiology. Portable radiology units capable of generating 70–80 KV combined with high-speed film and cassettes, allow today's equine practitioner easy capability of radiography of the equine skull. Radiology has been felt to be of limited value in the assessment of soft tissue or bone lesions near the gingival margins or exposed crown portion of the tooth.⁵ Radiology utilizing the open-mouth technique can aid in the diagnosis and treatment planning of many of the more challenging and often frustrating equine dental cases.

Open-mouth films bring the upper and lower occlusal surfaces out of contact and decrease super-imposition of the right and left arcades. Dixon et al. recently evaluated the open-mouth oblique radiographic projections for diagnosing lesions of the erupted or clinical crown.^a The same open-mouth technique can be used with standard radiographic projections—both lateral as well as oblique. DV open-mouth radiographic projections can show the entire circumference of the tooth crown.

The open-mouth standing radiograph has been found to be helpful in the diagnosis of many dental conditions. The owner and/or trainer appreciates having a definitive diagnosis and a prognosis for further soundness. Treatment planning is greatly enhanced, thus improving results of therapy with patient, owner, and trainer cooperation and satisfaction.

DENTISTRY

5. Conclusion

Heavy patient sedation and a stand to support the horse's head and radiographic cassette decreases motion when taking skull radiographs. Being able to support or prop the cassette against a motionless horse's head decreases the need for horse and cassette handlers. Wedging the mouth open for all oral radiographic exposures brings the incisors and four cheek tooth arcades out of contact. This decreases the superimposition that has historically blurred occlusal surfaces and made interpretation of exposed crown defects difficult. The above-described open-mouth radiograph protocol allows the tooth to be evaluated radiographically from the apex to the exposed crown. Open-mouth radiographs are invaluable tools for the equine practitioner in the diagnosis and treatment of all types of dental abnormalities. "We now look and are able to see more clearly".

References and Footnote

1. Covey SR. *The seven habits of highly effective people*. New York: Simon and Schuster, 1989;29–32.
2. Finn ST, Park RD. Radiology of the nasal cavity and paranasal sinuses in the horse. *Proc Am Assoc Equine Pract* 1987;33:383–397.
3. Lane JG, Gibbs C, Meynink S, Steele FC. Radiographic examination of the facial, nasal and paranasal regions of the horse: indications and procedures in 235 cases. *Equine Vet J* 1987;19:466–473.
4. Gibbs C. Dental imaging. In: Baker GJ, Easley J, eds. *Equine dentistry*. London: W.B. Saunders, 2000;139–172.
5. Pascoe JR. Dental radiography/radiology. *Proc Am Assoc Equine Pract* 1991;37:99–111.
6. Youatt W. *The horse*. Skinner JS, ed. New York: Leavitt and Allen Publishing, 1843;151.
7. O'Conner JJ. *Dollar's veterinary surgery*. 4th ed. Chicago: Alexander Eger, 1950;591–603.
8. Baker GJ. Abnormalities of wear and periodontal disease. In: Baker GJ, Easley J, eds. *Equine dentistry*. London: W.B. Saunders, 2000;70–78.
9. Uhliger C. Survey of selected dental abnormalities in 233 horses. *Proc Am Assoc Equine Pract* 1987;33:577–583.
10. Dixon PM, Tremaine WH, Pickles K, et al. Equine dental disease, part 2: a long-term study of 400 cases: disorders of development and eruption and variations in position of the cheek teeth. *Equine Vet J* 1999;31:519–528.
11. Tietze S, Becker M, Bockenhoff G. Computed tomographic evaluation in head diseases in the horse: 15 cases. *Equine Vet J* 1996;28:98–105.
12. Tucker RI, Farrell E. Computed tomography and magnetic resonance imaging of the equine head. *Vet Clin North Am Equine Pract* 2001;17:131–144.
13. Weller R, Livesey L, Nuss K, et al. Comparison of radiography and scintigraphy in the diagnosis of dental disorders in the horse. *Equine Vet J* 2001;33:49–58.

^aBarakzai SZ, Dixon PM. A study of open-mouthed oblique radiographic projections for evaluating lesions of the erupted (clinical) crown, unpublished data.