

## A DESCRIPTIVE STUDY OF THE DENTITION OF LITHUANIAN HEAVY-DROUGHT HORSES

Kęstutis Maslauskas<sup>1</sup>, Riitta-Mari Tulamo<sup>2</sup>, Thomas McGowan<sup>3</sup>, Audrius Kučinskas<sup>1</sup>

<sup>1</sup>*Department of Non-infectious Diseases, Lithuanian Veterinary Academy, Tilžės g. 18, LT-47181 Kaunas, Lithuania, Tel.: +37037363404; e-mail: kestutis.maslauskas@lva.lt*

<sup>2</sup>*Department of Equine and Small animal medicine, Faculty of Veterinary Medicine, University of Helsinki, Box 57 (Viikintie 49), FIN-00014, Finland.*

<sup>3</sup>*Faculty of Natural Resources Agriculture and Veterinary Science, University of Queensland, Gatten QLD 4343, Australia.*

**Summary.** The purpose of this study was to report the findings of the clinical examination of the teeth in the Lithuanian heavy-drought horse breed. In total, fifty horses were clinically examined. This is likely the very first time the dental examinations were performed in these horses.

Clinical examination of the teeth of the horses was made to initiate their health care management. A Triadan tooth numbering system was used in order to document the findings and to analyse the results (Foster, 1996).

The main dental finds were sharp enamel points on maxillary and mandibular cheek teeth, rostral hooks, wave mouth, step mouth, ramps, carries and buccal mucosal ulcers.

The results of this research suggest that it is purposeful to continue dental research for the whole population of the Lithuanian heavy-drought horses as a part of their health care program. Regular dental care is important for the welfare of the horse and especially in keeping and sustaining the national Lithuanian breed.

**Key words:** the upper and lower cheek teeth, wolf teeth, rostral hooks, wave mouth, clinical examination of the teeth.

## LIETUVOS SUNKIŲJŲ ARKLIŲ DANTŲ BŪKLĖS TYRIMAS

Kęstutis Maslauskas<sup>1</sup>, Riitta-Mari Tulamo<sup>2</sup>, Thomas McGowan<sup>3</sup>, Audrius Kučinskas<sup>1</sup>

<sup>1</sup>*Neužkrečiamųjų ligų katedra, Lietuvos veterinarijos akademija, Tilžės g. 18, LT-47181 Kaunas; tel. 370 37 36 34 04; el. paštas: kestutis.maslauskas@lva.lt*

<sup>2</sup>*Arklių ir smulkiųjų gyvūnų medicinos katedra, Veterinarinės medicinos fakultetas, Helsinkio universitetas, Box 57 (Viikintie 49), FIN-00014, Suomija*

<sup>3</sup>*Natūraliųjų išteklių, žemės ūkio ir veterinarijos mokslų fakultetas, Kvinslendo universitetas, Gatten QLD 4343, Australija*

**Santrauka.** Šio tyrimo tikslas – pristatyti klinikinio nacionalinės Lietuvos sunkiųjų veislės arklių dantų būklės tyrimo rezultatus. Kliniškai ištirta penkiasdešimt arklių. Mūsų duomenimis, pilnas dantų būklės tyrimas šios veislės arkliams atliktas pirmą kartą.

Tyrimas atliktas norint sukurti šių arklių sveikatingumo kontrolės programą. Trinarė dantų žymėjimo sistema taikyta užrašant ir analizuojant gautus rezultatus (Foster, 1996).

Pagrindiniai nustatyti dantų pakyciai yra aštrūs emalio taškai ant viršutinio ir apatinio žandikaulio kaplių bei krūminių dantų, priekiniai užkarbiai, banguoti, laiptuoti nauaugimai, rampos ant kaplių ir krūminių dantų, ėduonis ir žaizdos žandų gleivinėje. Tyrimo rezultatai parodė, jog pilną klinikinį dantų būklės tyrimą pagal sveikatingumo kontrolės programą tikslinga atlikti visiems Lietuvos sunkiųjų veislės arkliams. Tas svarbu ne tik arklių gerovei, bet ir išlaikant šią saugotiną Lietuvos nacionalinę veislę.

**Raktažodžiai:** aštrūs emalio taškai ant viršutinio ir apatinio žandikaulio kaplių bei krūminių dantų, priekiniai užkarbiai, vilkdančiai, banguoti, laiptuoti nauaugimai, klinikinis dantų būklės tyrimas.

**Introduction.** Lithuanian heavy-drought horses are hardy, have well-developed muscles, able-bodied, alert and have a good character, prolific and long-lived. They were interbred with the Swedish Ardenner horses that were imported during the years 1963, 2000 and 2001. The precarious state has been established for the Lithuanian heavy-drought horses presently (Šveistienė, 2005). In order to sustain Lithuanian heavy-drought breed it is important not only to maintain purposeful breeding program and good management but it is a prerequisite to have a planned control program of their health status (or health care program) as well.

Dentistry and treating diseases of the horses teeth are important in the veterinary practice. Currently in Lithuania there is no recommendation for the use of preventative veterinary dental care. Many authors point out that diseases of the horses teeth are the cause of the disorders of the other body systems (Knottenbelt, 1999). Signs commonly associated with dental problems are colic, quidding (spilling of rolled/chewed hay), spilling of feed, weight loss, excessive salivation, halitosis (bad smelling breath), nasal discharge, resistance to engage the bit and resistance to travelling on the right or the left rein (Dixon and Dacre 2005; Du Toit et al., 2008). Further, there are some au-

thors that suggest that dental disorders are related to clinical signs where the relationship is not so obvious. For example, horses showing signs of lameness, where the lameness is alleviated when dental problems are corrected (Baker, 1998). The clinical signs of dental diseases in the horse may also be undetected for a long time by the owner or by the veterinarian even during the common clinical examination of the horse (Uhlinger, 1987). In a 2006 study of horses with chronic weight loss, dental disorders were the cause in 20% of cases (Tamzali, 2006).

Some authors have been investigating the horses teeth and found that dental diseases are very common and associated with oral pathology. In 500 horse heads collected from an abattoir and examined, 80% had dental diseases associated with oral pathology. The age of the horses examined ranged from 6 months to 30 years of age (Kirkland et al., 1994).

On Prince Edward Island, Canada, Christie et al. found that 63% of horses had never had a veterinary dental examination. Furthermore, the horses which had their teeth examined, only 40.5% of them had their teeth examined at least once a year (Christie et al., 2004).

Dental examination should be included in the annual veterinary examination, thus allowing for early detection and treatment of dental problems. With an improved understanding of the prevalence of dental disease and the normal morphology of equine teeth, the science of equine dentistry can make valuable contributions to the health and well being of horses (Kirkland et al., 1994).

Lithuanian heavy-drought horses represent the national Lithuanian breed. However, to the authors knowledge, there have been no descriptive studies of dental disease in this breed. Therefore, we felt it important to investigate Lithuanian heavy-drought horses and their dental health in Lithuania.

## Materials and methods.

### Population

The horses were from private stables and it was agreed with the owners to use them in our research.

### Clinical data

Altogether 50 horses were examined. There were 11 stallions and 39 mares and horses were grouped according to their age: Group A: from two to four years ( $n = 11$ ), Group B: from five to six years ( $n = 11$ ), Group C: from seven to nine years ( $n = 13$ ), Group D: from ten to twenty years ( $n = 15$ ).

The following equipment were used: 1) a full mouth Haussmann type speculum<sup>a</sup>; 2) a light source "Mini Mag-Lite"<sup>a</sup>; 3) flexible fiber-optic extension for Mag-Lite AA<sup>a</sup> for examination of cavities; 4) a mouth piece for holding Mag-Lite AA<sup>a</sup> between teeth of the examiner 5) a 400 ml dosing syringe<sup>a</sup> 6) Equivet telescopic dental mirror<sup>a</sup>; 7) a dental stick<sup>a</sup> for the investigation of interdental spaces; 8) equine dental evaluation and maintenance form (Easley 1999 a); 9) digital camera Sony DSC-P52<sup>b</sup> for keeping the digital images of the teeth of the each horse.

<sup>a</sup>Kruuse, Denmark

<sup>b</sup>Sony Corporation, Japan

### Results.

*Abnormal dental findings according the horses age* (Table 1). A Triadan tooth numbering system was used in order to document the findings and to analyse the results (Foster, 1996; Figures 1 and 2).

*Group A: from 2–4 years (n=11)*

*Cheek teeth:* Sharp enamel points on the buccal edges of the maxillary and lingual edges of the mandibular cheek teeth were found in 90.9% (10/11) horses examined in group A (Table 1). Rostral hooks were found only in 27.2% (3/11) horses. Ramps were found in 9.1% (1/11) and wave mouth was found in one horse, too.

Table 1 **The summary of the main dental finds in Lithuanian heavy-drought horses.** Group a: 2–4 years, group b: 5–6 years, group c: 7–9 years, group d: 10–20 years. Sep-sharp enamel points; max=maxilla; man=mandible; ♂=stallion; ♀=mare

| Horses (Lithuanian Heavy-drought) |                  | Findings   |                 |    |                |   |                |   |               |   |            |   |       |   |            |   |        |                       |   |                            |   |  |   |                 |   | Total |    |    |    |
|-----------------------------------|------------------|--|-----------------|----|----------------|---|----------------|---|---------------|---|------------|---|-------|---|------------|---|--------|-----------------------|---|----------------------------|---|--|---|-----------------|---|-------|----|----|----|
|                                   |                  | Cheek teeth (106–111; 206–211; 306–311; 406–411) |                 |    |                |   |                |   |               |   |            |   |       |   |            |   |        | Wolf teeth (105; 205) |   | Canines (104;204; 304;404) |   | Incisors (101-103; 201-203;301-303; 401-403) |   | Mucosal lesions |   |       |    |    |    |
| Group                             | Number of horses |  | SEP (MAX + MAN) |    | SEP (MAN only) |   | SEP (MAX only) |   | Rostral Hooks |   | Wave mouth |   | Ramps |   | Step mouth |   | Caries |                       | ♂ | ♀                          | ♂ | ♀  | ♂ | ♀               | ♂ | ♀     | ♂  | ♀  |    |
|                                   | ♂                | ♀  | ♂               | ♀  | ♂              | ♀ | ♂              | ♀ | ♂             | ♀ | ♂          | ♀ | ♂     | ♀ | ♂          | ♀ | ♂      | ♀                     | ♂ | ♀                          | ♂ | ♀  | ♂ | ♀               | ♂ | ♀     | ♂  | ♀  |    |
| Group A                           | 2                | 9  | 2               | 8  |                |   |                |   | 1             | 2 | 1          |   |       | 1 |            |   |        |                       |   | 2                          | 3 |  |   | 2               | 4 |       | 2  | 8  | 20 |
| Group B                           | 4                | 7  | 3               | 5  | 1              | 2 |                |   |               | 2 |            | 1 |       |   |            |   |        |                       |   | 2                          | 3 | 1  |   | 1               | 3 |       |    | 8  | 16 |
| Group C                           | 3                | 10   | 2               | 8  |                |   |                |   | 1             |   |            |   |       |   | 1          |   |        |                       |   | 1                          | 6 |  | 1 | 1               |   |       |    | 6  | 15 |
| Group D                           | 2                | 13   | 2               | 5  |                | 3 |                |   | 2             | 2 |            | 1 |       | 3 | 1          | 3 |        | 1                     | 1 | 3                          |   | 4  | 1 | 1               |   | 1     | 7  | 27 |    |
| Total                             | 11               | 39   | 9               | 26 | 1              | 5 | 0              | 0 | 4             | 6 | 1          | 2 | 0     | 4 | 2          | 3 | 0      | 1                     | 6 | 15                         | 1 | 5  | 5 | 8               | 0 | 3     | 29 | 78 |    |

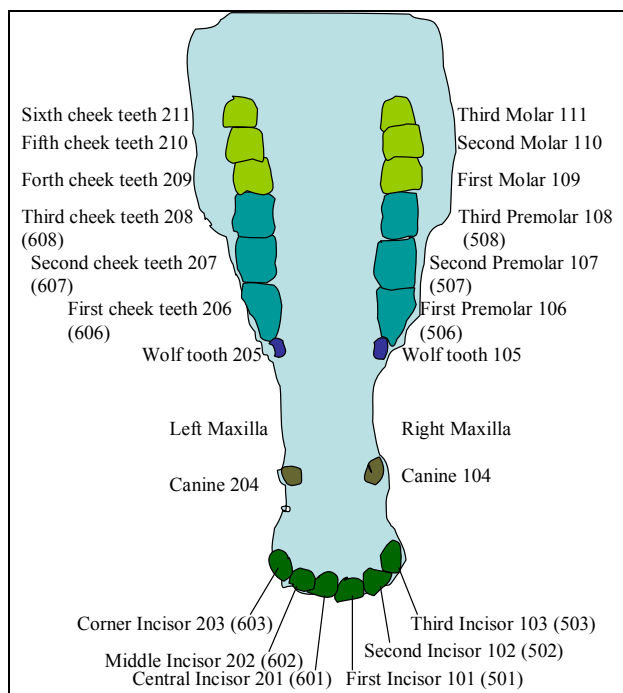


Figure 1. **Modified Triadan system- Maxilla**

The Modified Triadan system assigns a three digit number to each tooth (or each tooth space) in the mouth of the horse, based on its anatomical location. The first number describes the quadrant of the mouth as follows: the teeth of the right maxillary arcade all begin with the prefix 1; those of the left maxillary arcade, with 2; those of the mandibular left, with 3; those of the right mandibular arcade, with 4, respectively. Each quadrant is therefore numbered in clockwise fashion from the examiner's perspective (Foster, 1996).

*Wolf teeth:* The Wolf teeth were found altogether in 45.4% (5/11) horses in group A.

Group B: from 5–6 years (n=11)

*Cheek teeth:* Sharp enamel points on the buccal edges of the maxillary and the lingual edges of the mandibular cheek teeth were found in 72.7% (8/11) horses examined. Sharp enamel points on the lingual edges of the mandibular cheek teeth only were found in 27.2% (3/11). Rostral hooks were found in 18.1% (2/11) mares and wave mouth in 9.1% (1/11) mare.

*Wolf teeth, Canines, Incisors:* The Wolf teeth were found in 45.4% (5/11) horses in group B. There was tartar accumulation on the canines in 1/11 horses and erupting permanent incisors found in 1/11 horses. In one horse there was overbite of incisors and third deciduous incisor teeth retention also each in one horse. One first upper right incisor was broken.

Group C: from 7–9 years (n=13)

*Cheek teeth:* Sharp enamel points on the buccal edges of the maxillary and the lingual edges of the mandibular cheek teeth were found in 76.9% (10/13) horses examined. Rostral hooks were found in 7.7% (1/13) and step mouth also in one horse.

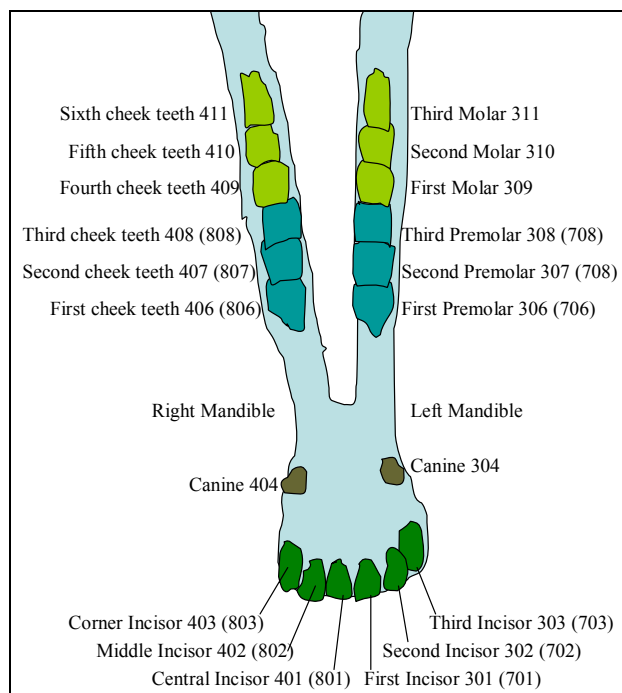


Figure 2. **Modified Triadan system- Mandible**

The permanent (adult) dentition utilizes numbers 1–4, and the deciduous (primary) dentition uses numbers 5–8. In each quadrant, the first or central incisor is always 01, with incisors numbered 01–03, and the canines, whether present or not, take up the 04 position in the formula. The premolars are numbered 05–08 and the molars are numbered 09–11 (Easley, 1999a).

*Wolf teeth, Canines, Incisors:* Wolf teeth were found in 53.8% (7/13). The rudimental canine teeth were also found in 1/13 horses as well as retention of the third deciduous teeth and overbite of incisors each in one horse.

Group D: from 10–20 years (n=15)

*Cheek teeth:* Sharp enamel points on the buccal edges of the maxillary and the lingual edges of the mandibular cheek teeth were found in 46.6% (7/15) horses examined. Sharp enamel points on the lingual edges of the mandibular cheek teeth only were found in 20% (3/15). Rostral hooks were evident in 26.6% (4/15) horses and wave mouth in 6.6% (1/15). Ramps were found in 20% (3/15) and step mouth in 26.6% (4/15) horses. Caries in the occlusal area on the both sides of the first two upper molars was found in one horse.

*Wolf teeth, Canines, Incisors:* Wolf teeth were found in 26.6% (4/15) horses. The rudimental canine teeth were found in 20% (3/15). In one horse there was overbite of incisors.

#### Discussion.

Several dental abnormalities were found in Lithuanian heavy- drought horses and they are discussed in the order of their frequency. Sharp enamel points were the most common (82%) dental pathology found in Lithuanian heavy-drought horses. Due the differential wear between the harder enamel and softer cementum and dentine, some enamel folds normally protrude on the cheek teeth occlusal surface, including medially on the mandibular and

laterally on the maxillary cheek teeth (Dixon and Dacre, 2005). This was also documented in the present study.

In a study by Brigham, 36/50 (72%) of the skulls examined had sharp enamel points in the teeth. In another survey it was found that 281/483 (58.3%) horses examined had sharp enamel points (Peters et al., 2006). These may cause buccal and lingual soft tissue trauma, therefore indicating that equine cheek teeth require routine rasping. Wilson (2005) in his study indicated that 261/537 horses (48.6%) only required floating of enamel points. It appears that some horses will develop the sharp enamel points during their life because of the specific conformation of their head. The arrangement of the teeth within the upper and lower arcades is such that the curve of the upper dental arcade is not fully accommodated by the conformation of the lower arcade, i.e. the lower arcade is straighter and the distance between the left and right arcades is less in the mandible than in the upper jaw (Baker, 1999a). Lithuanian heavy- drought horses are not an exception and develop the sharp enamel points too, which may be prevented by rasping.

Rostral hooks were also fairly common (20%) in the horses of this study. The 13/50 (26%) skulls examined showed focal dental overgrowths (Brigham and Duncanson, 2000). Partial elongations of the occlusal surface of teeth at either end of the cheek arcade which are not in occlusion are referred to as either hooks (pointed down) or ramps (pointed up) (Lowder and Mueller, 1998). Excessive rostral positioning of the maxillary cheek teeth in relation to the mandibular cheek teeth may result in enamel overgrowths on the rostral aspect of the first maxillary cheek tooth and on the caudal aspect of the sixth mandibular cheek tooth (Tremaine, 1997; Brigham and Duncanson, 2000). Hooks 106 and 206 may cause oral pain, bit pressure points and buccal surface calluses or ulcers (Baker, 2005). It is possible to treat the rostral hooks by hand float in the early stage, but if it is undetected for many years it will grow high and it will be possible to remove it only by using a motorised equipment.

Rostral hooks were also common in the Dutch study and 33.5% of the horses had rostral hooks but 25% also had caudal hooks (Peters et al., 2006). Even more hooks and peaks were found in review of 607 horses performed by Pimentel (2007) in altogether 1010 teeth with 495 (49.9%) rostral and 515 (50.1%) caudal hooks. On the other hand Wilson in his study had only 61/537 that had hooks present.

Abnormalities of wear such as ramps, hooks, wave, or step mouth may be caused by malpositioned teeth, asymmetrical deciduous premolar shedding, unequal eruption of opposing permanent teeth, central crown attrition, and infundibular cemental hypoplasia seen in maxillary cheek teeth (Rucker, 2007).

Ramps is defined as the presence of more crown in a rising 'ramp' on 309–311 and 409–411 (Baker, 1999b). Ramps (Triadan 306, 406) were found in Lithuanian heavy-drought horses (8%) too. Peters et al (2006) found 47/483 (9.7%) ramp cases and Wilson (2005) found 36/537 (6.7%) ramp cases. Our findings are thus in accordance with other studies. Ramps that form on the 306 and

406 can cause performance problems related to soft tissue trauma. They may force the mandible rostrally, putting extreme pressure on the temporomandibular joints. Mechanical forces on the 306 and 406 can cause the teeth to shift rostrally creating a diastema, which will lead to pocketing of feed and painful periodontal disease (Johnson and Porter, 2006). Also these can be prevented early by rasping.

Step mouth is extremely unequal wear of opposing teeth or dental extraction results in marked variations in the height of individual teeth and most often occurs between the third and fourth cheek teeth (Mueller, 1991). And it can be prevented by removing retained deciduous caps on the third cheek teeth in young horses. It is considered serious deficit and causes biting and chewing problems and abnormal wear of the teeth. Step mouth was found in 10% of the Lithuanian heavy- drought horses, which is fairly high compared with other studies. However, Peters et al. (2006) found only 4/483 (0.8%) stepped molar cases. It is important that the equine veterinary dentist keeps in mind that major malalignments have not occurred over a short period.

A wave mouth describes the uneven height associated with more than one tooth in an arcade. Normal attrition of the first molar, which is the first cheek tooth to erupt; and therefore, also the first to wear out, or the fourth premolar, missing teeth, tooth defects, and fractures of teeth or jaws can lead to a wave mouth (Bradley, 2002).

Wave mouth was found in 6% of the Lithuanian heavy-drought horses. Usually wave mouth is documented in about 3–8% of the horses (Brigham 2000, Peters et al., 2006, Pimentel et al., 2007, Wilson and Liyou 2005). Both step and wave mouth can be treated early with regular dental care.

Caries in the occlusal area on the both sides of the first two upper molars was a rare finding (2%) in our study. Peters et al. (2006) documented altogether 42/483 (8.7%) cemental hypoplasia cases. Caries is the dissolution of the calcified tissues of the teeth and occurs under a number of circumstances. In some environments, and under some feeding programs, foods that are cariogenic, i.e. caries forming, may adhere to the tooth crowns. The use of sweet feed, the high sugar content of molasses or the by-products of sweet- potato- processing plants produce a cariogenic diet (Baker, 1999c). The low number of caries in Lithuanian heavy- drought horses may be explained by theory of cariogenic diet mentioned above as they are mostly fed hay ad libitum only.

'Wolf tooth' (Triadan 105, 205) is the common term used to describe the first upper premolar. Forty to eighty per cent of domestic horses erupt upper wolf teeth, but it not unusual to only have one. These teeth usually erupt at 6 to 18 months of age but this is also quite variable. Because of the potential for problems, it is customary practice to extract wolf teeth in young horses that are used for performance (Easley, 1999b).

However, normal sized and positioned 'wolf teeth' are sometimes found in older riding horses competing to a very high level that have no history of biting problems (Dixon and Dacre, 2005). Wolf teeth (105; 205) were

found in Lithuanian heavy- drought horses (42%) during clinical teeth examination. In Brigham's (2000) study 2/50 (4%) of the skulls had wolf teeth. The reported incidence of wolf teeth has been 13% (Baker, 1979), 18.8% (Wilson and Liyou, 2005), 20.6% (Pimentel et al., 2007) and 31.9% (Wafa, 1988) indicating that the wolf teeth may have been removed from part of the horses (Brigham, 2000).

Disorders of incisors were also fairly common (26%) in the horses of this study. This included traumatic damage to teeth, retained deciduous incisors and overbite. Wilson (2005) found that 110/537 (20.5%) horses examined had a incisor abnormalities. In review by Dixon (1999) 44/400 cases (11%) suffer from primary disorders of their incisors. Because of their rostral position, equine incisors, in contrast to cheek teeth, are amenable to full visual examination (Dixon, 1999) so the abnormalities can be detected by the owner and corrected by veterinarian in their early stages.

Dental calculus on the canines (Triadan 104;204; 304; 404) was found (2%) in Lithuanian heavy- drought horses. As in a study by Brigham (2000) there were 7/50 animals (14%) that had bilateral calculus deposition (tartar) on the lower canines, but none had tartar on the upper canines. The lower canine teeth, lower incisors and buccal aspects of lower premolars are especially susceptible to gingivitis and periodontal disease secondary to tartar accumulation (Easley, 2005). Also these can be prevented early by removing tartar accumulations.

Required information on the normal morphology and effects of aging on equine teeth is currently being defined and may give new insight into the pathogenesis of dental disease in the horse (Kirkland et al., 1994). Authors concluded that the prophylactic dental procedures, with the subject to obtain the ideal functional occlusion is fundamental to dental arcade and oral cavity of horses sanity and not only float sharp enamel points. It becomes apparent that horses begin life with relatively uncomplicated mouths, and develop abnormalities as they age. Most of these abnormalities are preventable with regular maintenance. The equine practitioner must become skilled in the diagnosis of equine oral diseases and competent in the correct treatments of these diseases. The horse, the horse owner, and the veterinary profession all benefit from providing complete equine dental care (Pimentel et al., 2007; Carmalt, 2007; Wilson and Liyou 2005; Peters et al., 2006). American Association of Equine Practitioners recommends that every horse should have a dental exam performed at least once a year (American Association of Equine Practitioners, 2008).

### Conclusions.

The most common dental abnormalities found in the Lithuanian heavy-drought horses were sharp enamel points and rostral hooks and dental abnormalities and associated oral pathology were a common occurrence. Therefore, a complete oral examination every 6 to 12 months is recommended from the age of two years on to identify dental malocclusions or other dental pathologic conditions that may become clinically significant in time. At that age, the wolf teeth can be extracted if they inter-

fere with biting, the retained deciduous incisors and premolars can be removed, and permanent teeth eruption checked as well as the sharp enamel points controlled. From the five years on, the retained deciduous incisors and premolars can be removed, permanent teeth eruption checked and sharp enamel points controlled. To avoid the development of occlusal malalignments, such as wave and step mouths, clinical teeth examination once a year should be continued from the seventh year on. Rostral and caudal hooks and other pathologies can be detected and by removing them the mastication physiology of the horse can be restored. In horses older than ten years, wave, step or smooth mouth formation can be controlled by lowering the dominant teeth in the arcade. The removal of sharp enamel points will help in maintaining the physiology of mastication. Regular dental care is important for the welfare and in keeping and sustaining the national Lithuanian heavy-drought horse breed.

### References

1. American Association of Equine Practitioners. Internet: [www.aaep.org/horseowner](http://www.aaep.org/horseowner). 2008.
2. Baker G. J. Dental physical examination. *Vet. Clin. North Amer., Equine Pract.* 1998. Vol.14. P. 247–257.
3. Baker G.J. Dental Physiology In: Baker G.J., Easley J. (eds): *Equine dentistry*, 1<sup>st</sup> edn. Philadelphia: Elsevier/Saunders. 1999a. P. 29–34.
4. Baker G. J. Abnormalities of wear and periodontal disease In: Baker G.J., Easley J. (eds): *Equine dentistry*, 1<sup>st</sup> edn. Philadelphia: Elsevier/Saunders. 1999b. P. 72–73.
5. Baker G. J. Dental decay and endodontic disease In: Baker G.J., Easley J. (eds): *Equine dentistry*, 1<sup>st</sup> edn. Philadelphia: Elsevier/Saunders. 1999c. P. 79–84.
6. Baker G. J. Abnormalities of wear and periodontal disease In: Baker G.J., Easley J. (eds): *Equine dentistry*, 2<sup>nd</sup> edn. Philadelphia: Elsevier/Saunders. 2005. P. 111–119.
7. Bradley P. G. Dental care in the older horse. *Vet. Clin. North Amer., Equine Pract.* 2002. Vol. 18. P. 509–522
8. Brigham J.E., Duncanson G.R. An equine post-mortem dental study: 50 cases *Equine Vet. Educ.* 2000. Vol. 2. P. 79–82.
9. Carmalt J.L. Evidence-Based equine dentistry: preventive medicine. *Vet. Clin. North Amer., Equine Pract.* 2007. Vol. 23. P. 519–524.
10. Christie, J.L., Hewson, C.J., Riley, C.B., McNiven, M.A., Dohoo, I. R., Bate, L.A. Demographics, management, and welfare of nonracing horses in Prince Edward Island. *Can. vet. J.* 2004. Vol. 45. P. 1004–1011.
11. Dixon P.M., Tremaine W.H., Pickles K., Kuhns L., Hawe C., McCann J., McGorum B., Railton D. I., Brammer S. Equine dental disease Part 1: A long-term study of 400 cases: disorders of incisor, canine and first premolar teeth. *Equine vet. J.* 1999. Vol. 31. P. 369–377.
12. Dixon P.M., Dacre I. A review of equine dental disorders. *The Veterinary Journal.* 2005. Vol. 169. P. 165–187.
13. Du Toit, N., Gallagher, J., Burden, F.A., Dixon, P.M. Post mortem survey of dental disorders in 349 donkeys from an aged population (2005–2006). Part 2: Epidemiological studies. *Equine vet. J.* 2008. Vol. 40. P. 209–213.
14. Easley J. Dental and Oral Examination In: Baker G.J., Easley J. (eds): *Equine dentistry*, 1<sup>st</sup> edn. Philadelphia: Elsevier/Saunders, 1999a. P. 107–126.
15. Easley J. Equine tooth removal (exodontia) In: Baker G.J., Eas-

- ley J. (eds): Equine dentistry, 1<sup>st</sup> edn. Philadelphia: Elsevier/Saunders. 1999b. P. 223–224.
16. Easley J. Corrective Dental Procedures In: Baker G.J., Easley J. (eds): Equine dentistry, 2<sup>nd</sup> edn. Philadelphia: Elsevier/Saunders. 2005. P. 221–248.
  17. Foster D.L. Nomenclature for equine dental anatomy based on the modified Triadan system. Proceedings. Amer. Assoc. of Equine Pract. 1996. Vol. 42. P. 318–319.
  18. Johnson T.J., Porter C.M. Dental Overgrowths and Acquired Displacement of Cheek Teeth. American Association of Equine Practitioners- Equine Dentistry Focus Meeting, Ed: AAEP American Association of Equine Practitioners, Indianapolis, IN, USA. 2006.
  19. Knottenbelt D.C. The systemic effects of dental disease. In: Baker G.J., Easley J. (eds): Equine dentistry, 1<sup>st</sup> edn. Philadelphia: Elsevier/Saunders, 1999. P. 127–138.
  20. Kirkland K.D., Marett S.M., Inoue O.J., Baker G.J. Survey of equine dental disease and associated oral pathology. Proceedings. Amer. Assoc. of Equine Pract. 1994. Vol. 40. P. 119–120.
  21. Lowder M. Q., Mueller P.O.E. Dental disease in geriatric horses Vet. Clin. North Amer., Equine Pract. 1998. Vol. 14. P. 365–380.
  22. Mueller P.O.E. Equine dental disorders: cause, diagnosis, and treatment. Comp. Cont. Educ. Pract. Vet. 1991. Vol. 13. P. 1451–1460.
  23. Peters J.W.E., de Boer B., Broeze-ten G.B.M., Broeze J., Wiemer P., Sterk T., Spoomakers T.J.P. Survey of common dental abnormalities in 483 horses in the Netherlands. American Association of Equine Practitioners- Equine Dentistry Focus Meeting, Ed: AAEP American Association of Equine Practitioners, Indianapolis, IN, USA. 2006.
  24. Pimentel L.F.R.O., Zopa A., Alves G.E.S. & Amaral R.F. Equine dental disorders: review of 607 cases. Pesquisa Veterinaria Brasileira. 2007. Vol. 27. P. 109–110.
  25. Rucker B.A. How to detect Reoccurring Dental Malocclusions caused by Enamel Insufficiency. Proceedings. Amer. Assoc. of Equine Pract. 2007. Vol. 53. P. 504–506.
  26. Šveistienė R. Lietuvos sunkiųjų arklių veislė In: Lietuvos respublikos žemės ūkio ministerija, valstybinė gyvulių veislininkystės priežiūros tarnyba prie ŽŪM, valstybės įmonė žemės ūkio informacijos ir kaimo verslo centras (eds): Lietuvoje veisiami arkliai ir jų įvertinimai I tomas. Vilnius, 2005. P. 54–60.
  27. Tamzali Y. Chronic weight loss syndrome in the horse: a 60- case retrospective study. Equine Vet. Educ. Am. Ed. 2006. P. 372–380.
  28. Tremaine H., Dental care in horses. In practice. 1997. P. 186–199.
  29. Uhlinger C. Survey of selected dental abnormalities in 233 horses. Proceedings. Amer. Assoc. of Equine Pract. 1987. Vol. 33. P. 577–583.
  30. Wilson G.J., Liyou O.J. Examination of dental charts of horses presented for routine dentistry over a 12 month period. Austr. Equine vet. 2005. Vol. 24. P. 79–83.

Received 4 July 2008

Accepted 4 August 2008